A 31-year-old woman comes to the office due to transient visual changes that are characterized by "loss of vision for a minute" and commonly precipitated by bending forward or lifting objects. During the last 3 months, she has had persistent headaches that she attributes to migraines. The patient takes over-the-counter analgesics as needed. Blood pressure is 140/90 mm Hg and pulse is 72/min and regular. BMI is 32.4 kg/m^2. Funduscopic findings of the left eye are shown in the image below, with similar findings in the right eye.

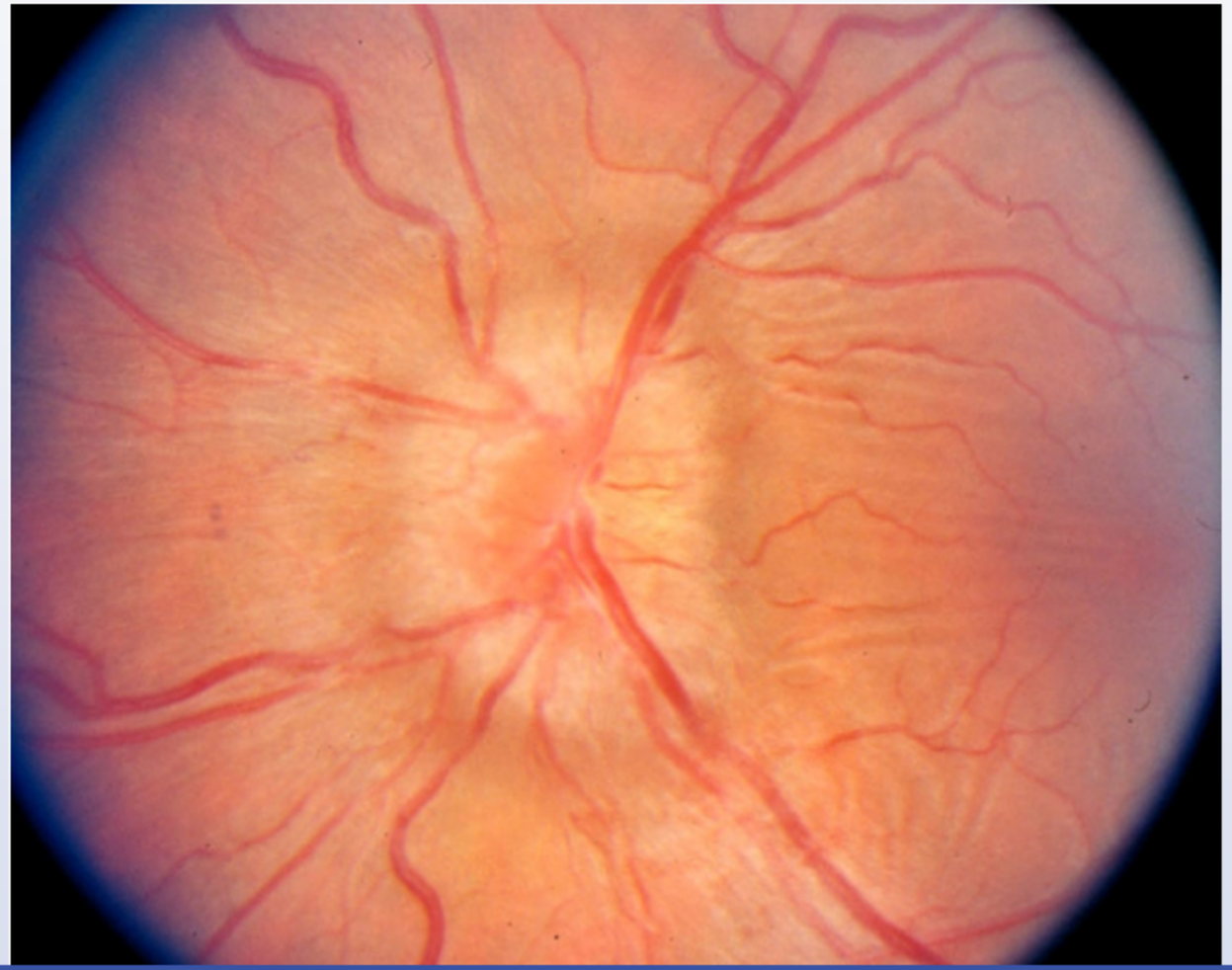

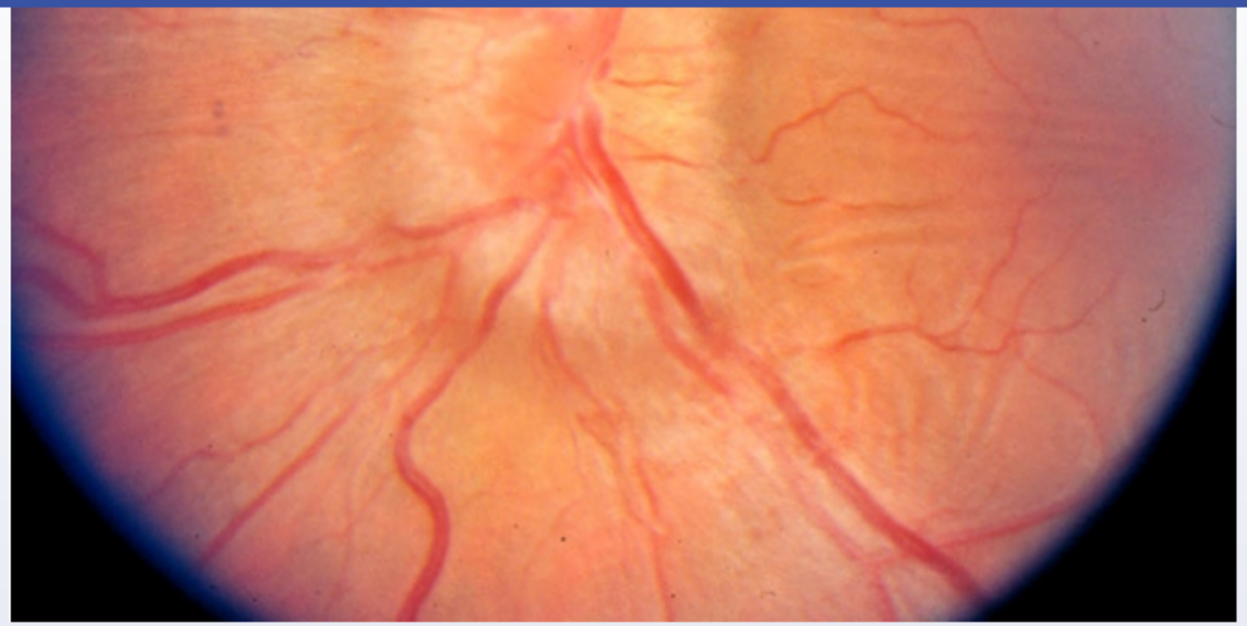

Which of the following is the most likely cause of the observed funduscopic findings in this patient?

A. Choroidal inflammation

B. Elevated intracranial pressure

C. Elevated intraocular pressure

D. Optic nerve inflammation

E. Retinal ischemia

Submit

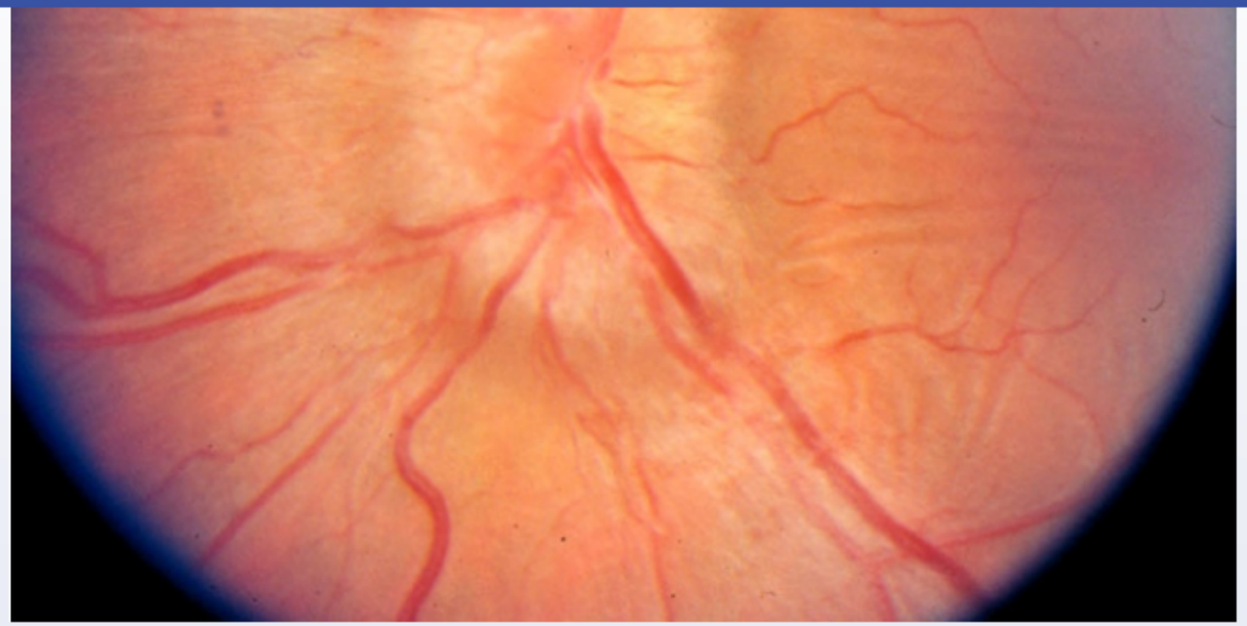

Which of the following is the most likely cause of the observed funduscopic findings in this patient?

- A. Choroidal inflammation (0%)
- ✓ B. Elevated intracranial pressure (70%)
- C. Elevated intraocular pressure (17%)
- D. Optic nerve inflammation (3%)
- E. Retinal ischemia (8%)

Omitted
Correct answer

70%
Answered correctly

07 secs
Time Spent

07/01/2020
Last Updated

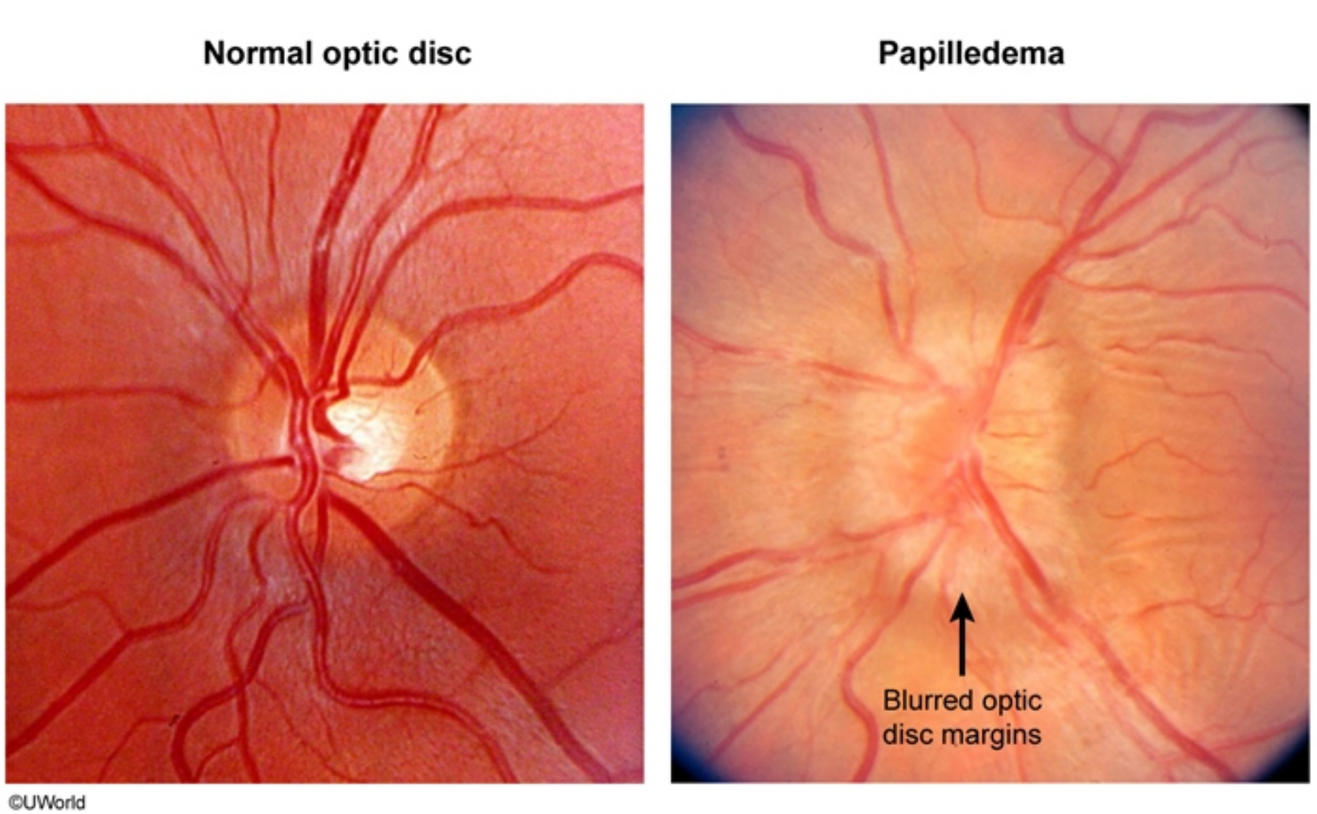

This patient's clinical presentation is consistent with **idiopathic intracranial hypertension** (pseudotumor cerebri). This condition typically presents in young obese women with **daily headache**, bilaterally symmetric papilledema, and **transient visual disturbances** related to impaired cerebral venous outflow and **elevated intracranial pressure**. Symptoms characteristically worsen during the Valsalva maneuver (eg, bending down, coughing) because intracranial pressure increases.

Increased intracranial pressure is transmitted through the cerebrospinal fluid in the subarachnoid space, which is continuous with the optic nerve sheath. This buildup of pressure compresses the optic nerves externally, which in turn **impairs axoplasmic flow** within the **optic nerves**, causing bilateral optic disc edema **(papilledema)**. Funduscopy shows elevation of the optic disc with blurred disc margins.

cerebral venous outflow and **elevated intracranial pressure**. Symptoms characteristically worsen during the Valsalva maneuver (eg, bending down, coughing) because intracranial pressure increases.

Increased intracranial pressure is transmitted through the cerebrospinal fluid in the subarachnoid space, which is continuous with the optic nerve sheath. This buildup of pressure compresses the optic nerves externally, which in turn **impairs axoplasmic flow** within the **optic nerves**, causing bilateral optic disc edema **(papilledema)**. Funduscopy shows elevation of the optic disc with blurred disc margins.

(Choice A) Choroidal inflammation is characteristic of posterior uveitis, which typically presents with painless vision loss and floaters. Ophthalmic examination may show inflammation/leukocytes in the vitreous humor. Uveitis is often associated with systemic inflammatory disorders (eg, inflammatory bowel disease, ankylosing spondylitis).

(Choice C) An acute increase in intraocular pressure is characteristic of angle-closure glaucoma, which typically presents with painful monocular vision loss, headache, vomiting, and conjunctival injection with a poorly reactive middilated pupil. Chronic increases in intraocular pressure can cause optic disc cupping due to atrophy of the optic nerve head. Glaucoma usually affects older individuals.

(Choice D) Optic neuritis is frequently associated with multiple sclerosis, a demyelinating CNS disease that typically affects women age 15-50. Although swelling of the optic disc can be present on funduscopy, optic neuritis usually causes sustained monocular vision loss over several weeks with painful eye movement rather than daily headaches with transient bilateral vision loss.

(Choice E) Retinal ischemia can manifest with painless transient monocular vision loss (amaurosis fugax) and is most commonly caused by atherosclerotic emboli originating from the ipsilateral carotid artery. Funduscopy may show embolic plaques and retinal whitening caused by ischemia. This condition typically affects older patients with vascular risk factors (eg, hypertension, hyperlipidemia, diabetes mellitus).

Educational objective:
Idiopathic intracranial hypertension (pseudotumor cerebri) presents in young obese women with daily headache (which worsens during the Valsalva maneuver), bilaterally symmetric papilledema, and transient visual disturbances. Increased intracranial pressure compresses the optic nerves, resulting in impaired axoplasmic flow and optic disc edema.

References

- Pathogenesis of optic disc edema in raised intracranial pressure.
- Pseudotumor cerebri: brief review of clinical syndrome and imaging findings.

Exhibit Display

Glaucomatous optic atrophy (advanced)

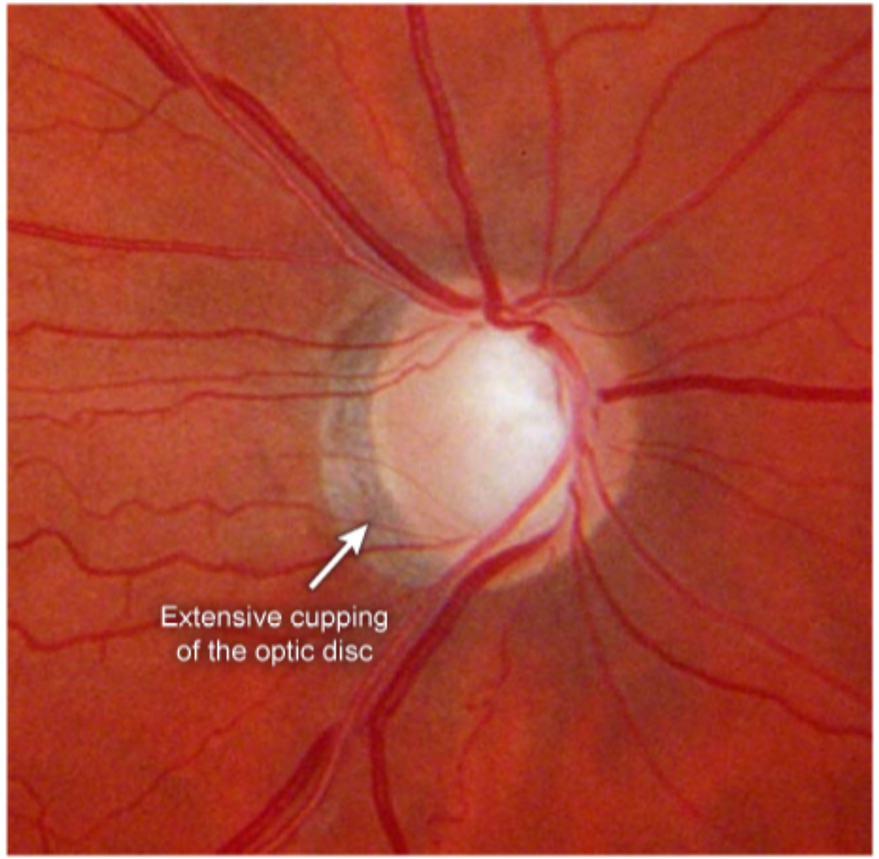

©UWorld

Zoom In | Zoom Out | Reset | Add To New Card | Existing Card

A 4-year-old boy is brought to the emergency department with dehydration. He has had several days of decreased oral intake, and today his parents could not get him to drink anything. The patient has received no vaccinations due to parental beliefs. Vital signs are normal except for mild tachycardia. Physical examination shows decreased skin turgor and sunken eyes. His jaw muscles are tight. Neurologic examination shows increased tone throughout and 3+ patellar reflexes. There is a small, healed puncture wound on his lower leg. The father says that the boy fell on a piece of chain-link fence in their backyard last week. Release of which of the following neurotransmitters is most likely to be directly impaired in this patient?

- A. Acetylcholine
- B. Dopamine
- C. Glutamate
- D. Glycine
- E. Serotonin

Submit

A 4-year-old boy is brought to the emergency department with dehydration. He has had several days of decreased oral intake, and today his parents could not get him to drink anything. The patient has received no vaccinations due to parental beliefs. Vital signs are normal except for mild tachycardia. Physical examination shows decreased skin turgor and sunken eyes. His jaw muscles are tight. Neurologic examination shows increased tone throughout and 3+ patellar reflexes. There is a small, healed puncture wound on his lower leg. The father says that the boy fell on a piece of chain-link fence in their backyard last week. Release of which of the following neurotransmitters is most likely to be directly impaired in this patient?

- A. Acetylcholine (28%)
- B. Dopamine (1%)
- C. Glutamate (13%)
- ✓ D. Glycine (56%)
- E. Serotonin (0%)

Omitted
Correct answer
D

56%
Answered correctly

02 secs
Time Spent

05/30/2020
Last Updated

Explanation

Tetanus

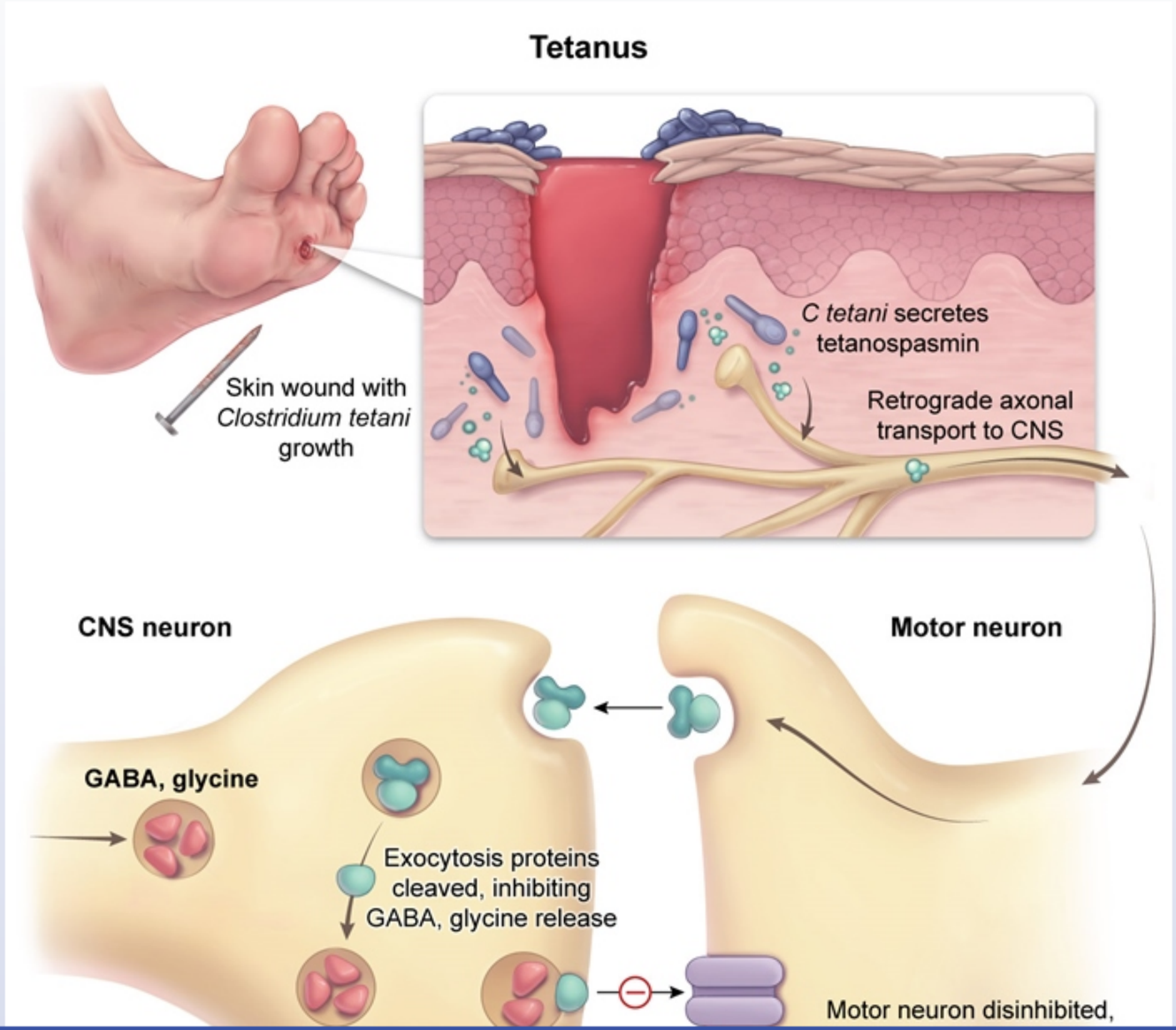
Tetanus
Skin wound with
Clostridium tetani
growth
C tetani secretes
tetanospasmin
Retrograde axonal
transport to CNS
CNS neuron
Motor neuron
GABA, glycine
Exocytosis proteins
cleaved, inhibiting
GABA, glycine release
Motor neuron disinhibited,

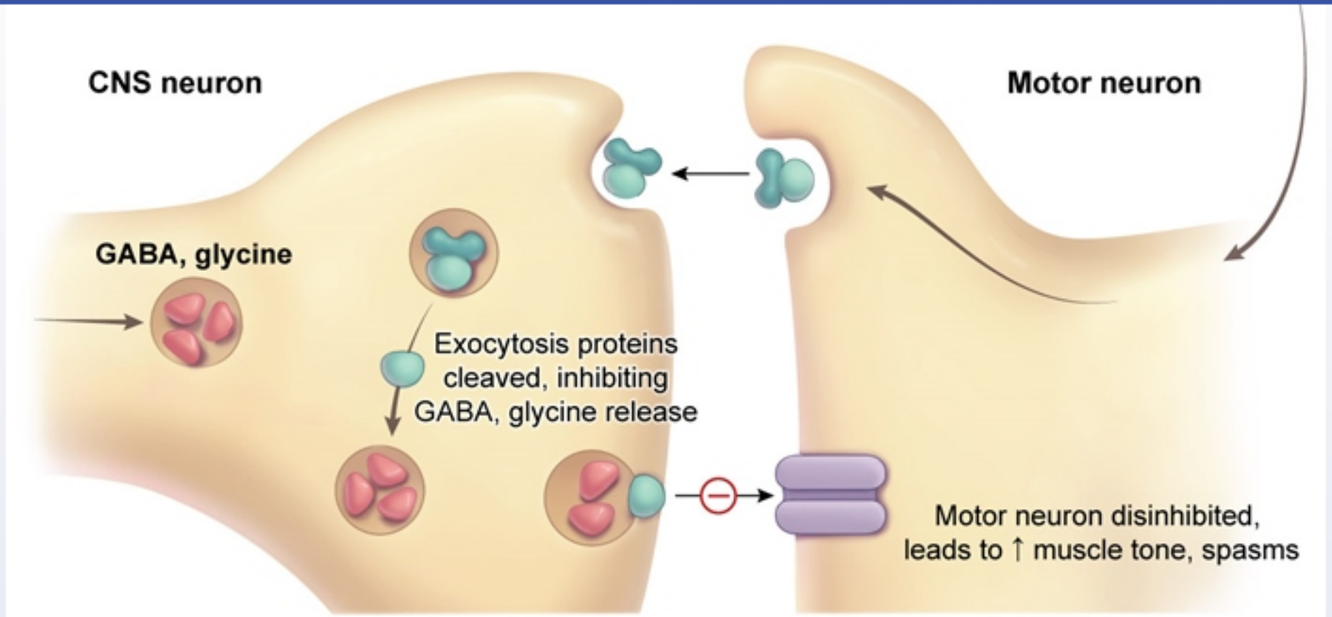

CNS = central nervous system.

©UWorld

This unvaccinated child has evidence of **tetanus** (*Clostridium tetani* infection) following a puncture wound. *C tetani* causes disease not through tissue invasion but by producing a potent metalloprotease **exotoxin** (tetanospasmin) that is deadly in nanogram quantities. The toxin first binds to receptors on the presynaptic membranes of peripheral motor neurons. From there, it migrates by **retrograde axonal transport** to central inhibitory neurons in the spinal cord and brain stem and prevents release of the inhibitory neurotransmitters **glycine** and **gamma-aminobutyric acid (GABA)**. Suppression of inhibitory nerve activity results in **increased activation** of motor nerves, causing **muscle spasms** and **hyperreflexia**. Classic features include difficulty opening the jaw (lockjaw, or **trismus**), a fixed sardonic smile (risus sardonicus), and contractions of back muscles resulting in backward arching (**opisthotonos**). Patients are also extremely irritable and develop tetanic spasms in response to minor stimuli such as loud noises.

(Choice A) Acetylcholine release is inhibited by the botulinum toxin from *C botulinum*, leading to the flaccid paralysis seen in clinical botulism.

(Choices B and C) Neither dopamine nor glutamate release has been linked to toxin effects in humans.

CNS = central nervous system.

©UWorld

This unvaccinated child has evidence of **tetanus** (*Clostridium tetani* infection) following a puncture wound. *C tetani* causes disease not through tissue invasion but by producing a potent metalloprotease **exotoxin** (tetanospasmin) that is deadly in nanogram quantities. The toxin first binds to receptors on the presynaptic membranes of peripheral motor neurons. From there, it migrates by **retrograde axonal transport** to central inhibitory neurons in the spinal cord and brain stem and prevents release of the inhibitory neurotransmitters **glycine** and **gamma-aminobutyric acid (GABA)**. Suppression of inhibitory nerve activity results in **increased activation** of motor nerves, causing **muscle spasms** and **hyperreflexia**. Classic features include difficulty opening the jaw (lockjaw, or **trismus**), a fixed sardonic smile (risus sardonicus), and contractions of back muscles resulting in backward arching (**opisthotonos**). Patients are also extremely irritable and develop tetanic spasms in response to minor stimuli such as loud noises.

(Choice A) Acetylcholine release is inhibited by the botulinum toxin from *C botulinum*, leading to the flaccid paralysis seen in clinical botulism.

(Choices B and C) Neither dopamine nor glutamate release has been linked to toxin effects in humans.

(Choice E) Serotonin release from enterochromaffin cells in the gastrointestinal tract is stimulated by *Vibrio cholera* enterotoxin. This increased serotonin release contributes to the extreme fluid secretion seen in cholera.

Educational objective:
Tetanospasmin is a neuro-exotoxin released by *Clostridium tetani*. The toxin blocks the release of glycine and gamma-aminobutyric acid (GABA) from the spinal inhibitory interneurons that regulate the lower motor neurons. These disinhibited motor neurons cause increased activation of muscles, leading to spasms and hyperreflexia.

Pathophysiology	Nervous System	Tetanus
Subject	System	Topic

Copyright © UWorld. All rights reserved.

1
2
3
4
5
6
7
8
9
10
11
12
13
14
15
16
17
18
19
20
21
22
23
24
25
26
27
28
29

A 34-year-old man comes to the emergency department complaining of weakness, dizziness, and paresthesias involving his face and extremities. He has never had symptoms like this before. Two hours earlier, he ate fish at a new Japanese restaurant. Neurological examination shows reduced muscle strength and decreased deep-tendon reflexes. Which of the following parts of the action potential curve is most likely impaired in this patient?

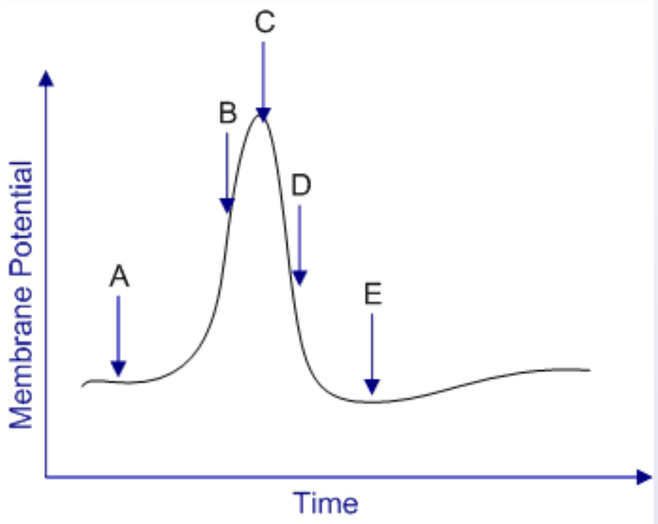

A. A
B. B
C. C
D. D
E. E

He has never had symptoms like this before. Two hours earlier, he ate fish at a new Japanese restaurant. Neurological examination shows reduced muscle strength and decreased deep-tendon reflexes. Which of the following parts of the action potential curve is most likely impaired in this patient?

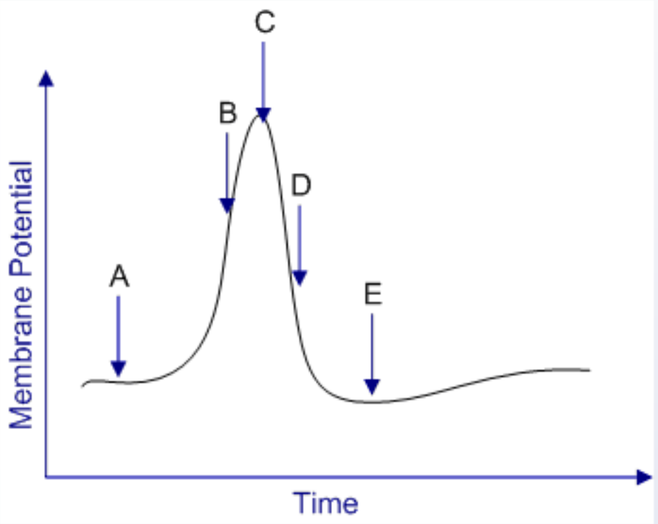

A. A (7%)
✓ B. B (74%)
C. C (5%)
D. D (8%)
E. E (4%)

Omitted
Correct answer

74%
Answered correctly

06 secs
Time Spent

06/24/2020
Last Updated

Voltage-gated sodium channel toxins	
Tetrodotoxin (puffer fish)	Binds to Na^+ channels, inhibiting Na^+ influx and preventing action potential conduction
Saxitoxin (dinoflagellates in "red tide")	
Ciguatoxin (exotic fish, Moray eel)	Binds to the Na^+ channel, keeping it open and causing persistent depolarization
Batrachotoxin (South American frogs)	

This patient's constellation of symptoms (ie, paresthesias, weakness, dizziness, nausea) and history of fish consumption are strongly suggestive of food poisoning by pufferfish, a Japanese delicacy. Pufferfish can be lethal if not properly prepared. It is necessary to remove the organs containing high quantities of tetrodotoxin, a toxin produced by microorganisms associated with the fish.

Tetrodotoxin binds to voltage-gated sodium channels in nerve and cardiac tissue, preventing sodium influx and depolarization. Symptoms of tetrodotoxin poisoning occur quickly after ingestion and include dizziness, weakness, loss of reflexes, paresthesias of the face and extremities, nausea, vomiting, and diarrhea. Higher exposures can cause severe hypotension and general paralysis; death can occur from respiratory failure and hypotension. Treatment includes supportive care and intestinal decontamination with gut lavage and charcoal.

(Choice A) The resting potential is equal to approximately -70 mV. It is maintained by high membrane K^+ permeability and low Na^+permeability. K^+ efflux occurs via non-gated K^+ channels (leak channels).

(Choice C) Overshoot represents the maximal value of the action potential during which the membrane potential is positive. At this point, open sodium channels become inactivated and close, preventing further increase in the membrane potential.

(Choice D) Repolarization results from closure of Na^+ channels and simultaneous opening of K^+ channels. This results in a sharp decrease in Na^+ conductance and a significant increase in K^+ conductance. Potassium efflux is responsible for returning the membrane potential to the resting potential.

(Choice E) Hyperpolarization occurs for a short moment following repolarization due to the slow closure of voltage-gated potassium channels.

of food poisoning by pufferfish, a Japanese delicacy. Pufferfish can be lethal if not properly prepared. It is necessary to remove the organs containing high quantities of tetrodotoxin, a toxin produced by microorganisms associated with the fish.

Tetrodotoxin binds to voltage-gated sodium channels in nerve and cardiac tissue, preventing sodium influx and depolarization. Symptoms of tetrodotoxin poisoning occur quickly after ingestion and include dizziness, weakness, loss of reflexes, paresthesias of the face and extremities, nausea, vomiting, and diarrhea. Higher exposures can cause severe hypotension and general paralysis; death can occur from respiratory failure and hypotension. Treatment includes supportive care and intestinal decontamination with gut lavage and charcoal.

(Choice A) The resting potential is equal to approximately -70 mV. It is maintained by high membrane K^+ permeability and low Na^+permeability. K^+ efflux occurs via non-gated K^+ channels (leak channels).

(Choice C) Overshoot represents the maximal value of the action potential during which the membrane potential is positive. At this point, open sodium channels become inactivated and close, preventing further increase in the membrane potential.

(Choice D) Repolarization results from closure of Na^+ channels and simultaneous opening of K^+ channels. This results in a sharp decrease in Na^+ conductance and a significant increase in K^+ conductance. Potassium efflux is responsible for returning the membrane potential to the resting potential.

(Choice E) Hyperpolarization occurs for a short moment following repolarization due to the slow closure of voltage-gated potassium channels. The membrane potential becomes more negative than the normal resting potential and approaches the K^+ equilibrium potential of -85 mV. When the voltage-gated K^+ channels close, the membrane potential returns to the resting value.

Educational objective:
Pufferfish poisoning is caused by tetrodotoxin, a neurotoxin produced by microorganisms associated with the fish. Tetrodotoxin binds to voltage-gated sodium channels in nerve and cardiac tissue, preventing sodium influx and depolarization.

References

- Tetrodotoxin: a brief history

Pathophysiology	Nervous System	Seafood poisoning
Subject	System	Topic

Copyright © UWorld. All rights reserved.

A 42-year-old man comes to the emergency department due to worsening jaw pain and stiffness. His symptoms began 2 days ago and have limited his ability to eat. Today the patient also developed painful stiffness in his neck. He has had no fever, chills, headache, focal weakness, or numbness. The patient is a farmer in rural Pennsylvania and sustained a wooden splinter injury to his forearm while working in a barn a week ago. He has no chronic medical conditions but has not had medical care for many years. On examination, the patient is not able to open his mouth. The muscles of the neck are tense, and neck range of motion is impaired. Which of the following is the best approach to establishing diagnosis in this patient?

A. Anaerobic blood culture

B. Cerebrospinal fluid analysis

C. Clinical diagnosis only

D. Serum toxin assay

E. Several sets of antibody titers

Submit

A 42-year-old man comes to the emergency department due to worsening jaw pain and stiffness. His symptoms began 2 days ago and have limited his ability to eat. Today the patient also developed painful stiffness in his neck. He has had no fever, chills, headache, focal weakness, or numbness. The patient is a farmer in rural Pennsylvania and sustained a wooden splinter injury to his forearm while working in a barn a week ago. He has no chronic medical conditions but has not had medical care for many years. On examination, the patient is not able to open his mouth. The muscles of the neck are tense, and neck range of motion is impaired. Which of the following is the best approach to establishing diagnosis in this patient?

- A. Anaerobic blood culture (8%)
- B. Cerebrospinal fluid analysis (7%)
- ✓ C. Clinical diagnosis only (36%)
- D. Serum toxin assay (45%)
- E. Several sets of antibody titers (2%)

Omitted
Correct answer
C

36%
Answered correctly

02 secs
Time Spent

04/14/2020
Last Updated

Explanation

Tetanus	
Cause	• ***Clostridium tetani*** spores inoculate skin wound → germinate → produce tetanus toxin → retrograde axonal transport to CNS → **blocks inhibitory interneurons**

Tetanus	
Cause	• ***Clostridium tetani*** spores inoculate skin wound → germinate → produce tetanus toxin → retrograde axonal transport to CNS → **blocks inhibitory interneurons** • Risk: incomplete childhood vaccines or lack of 10-year booster shot
Symptoms	• **Trismus** (lockjaw) & difficulty swallowing • Intermittent intense muscular spasms • Opisthotonos (extremely arched back) • Risus sardonicus (facial muscle spasm while smiling)
Prevention	• **Tetanus toxoid vaccination**

Tetanus is rare in the developed world due to widespread vaccination with tetanus toxoid. However, cases can occur in individuals who were incompletely vaccinated as a child or those who **have not received booster vaccination** every 10 years (as is likely in this patient who has not been under medical care). The majority of patients who develop tetanus have a history of a **puncture wound** (eg, splinter) approximately a week prior to symptoms, which led to inoculation with *Clostridium tetani* spores. The spores germinate in anaerobic conditions into vegetative, rod-shaped bacteria and produce tetanus toxin (tetanospasmin). Tetanus toxin travels through lower motor neurons to the central nervous system where it inactivates inhibitory interneurons. Common manifestations include masseter muscle spasm (**lockjaw** [trismus]), muscle pain and stiffness, and difficulty swallowing.

Tetanus is a **clinical diagnosis** that should be suspected in patients who have characteristic symptoms, particularly if they are unlikely to be adequately vaccinated or have a history of recent cutaneous trauma. Blood cultures are not helpful because *C tetani* only grows at the inoculation site (the clinical syndrome stems from toxin elaboration not bacterial invasion) **(Choice A)**. Wound cultures can provide supportive evidence but often take several days to return, so they are not usually performed.

(Choice B) The neurologic manifestations of tetanus are caused by toxin-mediated blockade of inhibitory interneurons at the level of the anterior horn cells. Cerebrospinal fluid testing is usually normal and is not typically part of diagnostic testing.

(Choice D) Serum tetanus toxin assay is not widely available and is not routinely used to diagnose tetanus. Tetanus is largely a clinical diagnosis.

Tetanus is rare in the developed world due to widespread vaccination with tetanus toxoid. However, cases can occur in individuals who were incompletely vaccinated as a child or those who **have not received booster vaccination** every 10 years (as is likely in this patient who has not been under medical care). The majority of patients who develop tetanus have a history of a **puncture wound** (eg, splinter) approximately a week prior to symptoms, which led to inoculation with *Clostridium tetani* spores. The spores germinate in anaerobic conditions into vegetative, rod-shaped bacteria and produce tetanus toxin (tetanospasmin). Tetanus toxin travels through lower motor neurons to the central nervous system where it inactivates inhibitory interneurons. Common manifestations include masseter muscle spasm (**lockjaw** [trismus]), muscle pain and stiffness, and difficulty swallowing.

Tetanus is a **clinical diagnosis** that should be suspected in patients who have characteristic symptoms, particularly if they are unlikely to be adequately vaccinated or have a history of recent cutaneous trauma. Blood cultures are not helpful because *C tetani* only grows at the inoculation site (the clinical syndrome stems from toxin elaboration not bacterial invasion) **(Choice A)**. Wound cultures can provide supportive evidence but often take several days to return, so they are not usually performed.

(Choice B) The neurologic manifestations of tetanus are caused by toxin-mediated blockade of inhibitory interneurons at the level of the anterior horn cells. Cerebrospinal fluid testing is usually normal and is not typically part of diagnostic testing.

(Choice D) Serum tetanus toxin assay is not widely available and is not routinely used to diagnose tetanus. Tetanus is largely a clinical diagnosis.

(Choice E) Positive antitoxoid serology indicates that an individual is likely to be adequately vaccinated and reduces the chances that a patient has tetanus.

Educational objective:
Tetanus is a clinical diagnosis that should be suspected in patients who have characteristic symptoms (eg, lockjaw, muscle pain/spasms, difficulty swallowing), particularly if they are unlikely to be adequately vaccinated or have an antecedent cutaneous injury.

Pathophysiology	Nervous System	Tetanus
Subject	System	Topic

Copyright © UWorld. All rights reserved.

A 22-year-old man is undergoing surgical repair of an inguinal hernia. Anesthesia is induced and an endotracheal tube is placed. He then develops severe spasm of the masseter muscles, and there is a dramatic increase in expired carbon dioxide measured from the endotracheal tube. His core body temperature begins to increase and is now 38.9 C (102 F). Which of the following is the most likely underlying mechanism leading to elevated body temperature in this patient?

A. Acute elevation of circulating free T4

B. Change in hypothalamic set point

C. Excessive myoplasmic calcium accumulation

D. Impaired cutaneous vasodilation

E. Increased serotonergic activity in the CNS

Submit

A 22-year-old man is undergoing surgical repair of an inguinal hernia. Anesthesia is induced and an endotracheal tube is placed. He then develops severe spasm of the masseter muscles, and there is a dramatic increase in expired carbon dioxide measured from the endotracheal tube. His core body temperature begins to increase and is now 38.9 C (102 F). Which of the following is the most likely underlying mechanism leading to elevated body temperature in this patient?

- A. Acute elevation of circulating free T4 (1%)
- B. Change in hypothalamic set point (11%)
- ✓ C. Excessive myoplasmic calcium accumulation (77%)
- D. Impaired cutaneous vasodilation (4%)
- E. Increased serotonergic activity in the CNS (5%)

Omitted
Correct answer
C

77%
Answered correctly

03 secs
Time Spent

03/25/2020
Last Updated

Explanation

Malignant hyperthermia	
Pathophysiology	• Genetic mutation of ryanodine receptors • Triggered by inhalational anesthetics & succinylcholine • Unregulated sarcoplasmic calcium release → sustained muscle contraction
	• Masseter muscle spasm

Malignant hyperthermia	
Pathophysiology	• Genetic mutation of ryanodine receptors • Triggered by inhalational anesthetics & succinylcholine • Unregulated sarcoplasmic calcium release → sustained muscle contraction
Clinical manifestations	• Masseter muscle spasm • Widespread muscle contraction (rigidity) • Hypercarbia • Rhabdomyolysis → hyperkalemia & acute renal failure • Hyperthermia (late manifestation)
Treatment	• Immediate cessation of causative anesthetic • Dantrolene

This patient with masseter muscle spasm, acute hypercarbia, and elevated temperature shortly after induction of anesthesia likely has **malignant hyperthermia** (MH), a condition characterized by excessive muscle contracture.

Normally, muscle contraction is mediated by a cascade of events:

- Membrane depolarization **releases calcium** from the sarcoplasmic reticulum into the intracellular space
- Calcium binds to troponin to expose myosin bridging sites
- Exposed myosin cross-links to actin and contracts
- Sarcoplasmic reticulum calcium ATPase reuptakes calcium to reverse this binding and cause relaxation

In patients with MH, exposure to certain **anesthetic agents** (eg, succinylcholine, inhalational gasses) causes unregulated passage of calcium from the sarcoplasmic reticulum into the intracellular space. **Excessive myoplasmic calcium accumulation** results in sustained muscle contraction, which is often first noted in the masseter.

Sustained muscle contraction leads to increased cellular metabolism, which causes **hypercarbia** and acidosis. Muscle hypermetabolism consumes ATP and leads to **excessive heat production**. Once ATP and oxygen stores are depleted, muscle breakdown (ie, rhabdomyolysis)

Normally, muscle contraction is mediated by a cascade of events:

- Membrane depolarization **releases calcium** from the sarcoplasmic reticulum into the intracellular space
- Calcium binds to troponin to expose myosin bridging sites
- Exposed myosin cross-links to actin and contracts
- Sarcoplasmic reticulum calcium ATPase reuptakes calcium to reverse this binding and cause relaxation

In patients with MH, exposure to certain **anesthetic agents** (eg, succinylcholine, inhalational gasses) causes unregulated passage of calcium from the sarcoplasmic reticulum into the intracellular space. **Excessive myoplasmic calcium accumulation** results in sustained muscle contraction, which is often first noted in the masseter.

Sustained muscle contraction leads to increased cellular metabolism, which causes **hypercarbia** and acidosis. Muscle hypermetabolism consumes ATP and leads to **excessive heat production**. Once ATP and oxygen stores are depleted, muscle breakdown (ie, rhabdomyolysis) occurs, which releases potassium, myoglobin, and creatine kinase, leading to a further cascade (eg, arrhythmias, acute renal failure, disseminated intravascular coagulation) that may be fatal. **Dantrolene** is used to treat MH because it blocks further release of calcium into the intracellular space.

(Choice A) Thyroid storm (ie, thyrotoxic crisis) can be precipitated by surgery. Hyperpyrexia occurs because excessive circulating levels of T3 and T4 increase cellular metabolism and adrenergic tone. However, thyroid storm does not cause sustained muscle contractions.

(Choice B) A true fever results from a change in the hypothalamic set point, typically due to an infection (not anesthesia). Shivering may occur, but not sustained muscle contraction or acute hypercarbia.

(Choice D) Heat dissipation occurs primarily by cutaneous vasodilation and sweating. These mechanisms can be impaired by aging or medications (eg, atropine). During an MH crisis, cutaneous heat removal is unaffected, but heat production far outstrips heat dissipation.

(Choice E) Excessive serotonergic activity in the CNS can result in hyperpyrexia (due to serotonin syndrome). However, it classically presents with hyperreflexia and clonus (rather than rigidity) and is seen in patients taking serotonergic medications (eg, selective serotonin reuptake inhibitors, tricyclic antidepressants), especially in combination, rather than with anesthesia.

Educational objective:
In patients with malignant hyperthermia, exposure to certain anesthetic agents (eg, succinylcholine, inhalational gasses) causes unregulated passage of calcium from the sarcoplasmic reticulum into the intracellular space. This results in sustained muscle contraction that leads to

Sustained muscle contraction leads to increased cellular metabolism, which causes **hypercarbia** and acidosis. Muscle hypermetabolism consumes ATP and leads to **excessive heat production**. Once ATP and oxygen stores are depleted, muscle breakdown (ie, rhabdomyolysis) occurs, which releases potassium, myoglobin, and creatine kinase, leading to a further cascade (eg, arrhythmias, acute renal failure, disseminated intravascular coagulation) that may be fatal. **Dantrolene** is used to treat MH because it blocks further release of calcium into the intracellular space.

(Choice A) Thyroid storm (ie, thyrotoxic crisis) can be precipitated by surgery. Hyperpyrexia occurs because excessive circulating levels of T3 and T4 increase cellular metabolism and adrenergic tone. However, thyroid storm does not cause sustained muscle contractions.

(Choice B) A true fever results from a change in the hypothalamic set point, typically due to an infection (not anesthesia). Shivering may occur, but not sustained muscle contraction or acute hypercarbia.

(Choice D) Heat dissipation occurs primarily by cutaneous vasodilation and sweating. These mechanisms can be impaired by aging or medications (eg, atropine). During an MH crisis, cutaneous heat removal is unaffected, but heat production far outstrips heat dissipation.

(Choice E) Excessive serotonergic activity in the CNS can result in hyperpyrexia (due to serotonin syndrome). However, it classically presents with hyperreflexia and clonus (rather than rigidity) and is seen in patients taking serotonergic medications (eg, selective serotonin reuptake inhibitors, tricyclic antidepressants), especially in combination, rather than with anesthesia.

Educational objective:
In patients with malignant hyperthermia, exposure to certain anesthetic agents (eg, succinylcholine, inhalational gasses) causes unregulated passage of calcium from the sarcoplasmic reticulum into the intracellular space. This results in sustained muscle contraction that leads to hypercarbia, hyperthermia, and acidosis.

References

- Malignant hyperthermia, a Scandinavian update.

Pathophysiology	Nervous System	Anesthesia
Subject	System	Topic

Copyright © UWorld. All rights reserved.

A 56-year-old woman is brought to the emergency department due to several days of progressive dyspnea, productive cough, and fever. Today, her son found her very short of breath and obtunded. The patient has a history of hypertension, type 2 diabetes mellitus, and long-standing rheumatoid arthritis. Examination reveals bilateral pneumonia and severe respiratory distress. The patient is lethargic without focal neurologic deficits. Urgent endotracheal intubation is performed for mechanical ventilation, and the patient is started on broad-spectrum antibiotics. Repeat examination 2 hours later shows that she has developed areflexic, flaccid paralysis of all extremities. Which of the following is the most likely cause of the neurologic deficits in this patient?

- A. Cerebral septic emboli
- B. Diabetic neuropathy
- C. Guillain-Barré syndrome
- D. Malignant hyperthermia
- E. Vertebral subluxation

Submit

A 56-year-old woman is brought to the emergency department due to several days of progressive dyspnea, productive cough, and fever. Today, her son found her very short of breath and obtunded. The patient has a history of hypertension, type 2 diabetes mellitus, and long-standing rheumatoid arthritis. Examination reveals bilateral pneumonia and severe respiratory distress. The patient is lethargic without focal neurologic deficits. Urgent endotracheal intubation is performed for mechanical ventilation, and the patient is started on broad-spectrum antibiotics. Repeat examination 2 hours later shows that she has developed areflexic, flaccid paralysis of all extremities. Which of the following is the most likely cause of the neurologic deficits in this patient?

- A. Cerebral septic emboli (24%)
- B. Diabetic neuropathy (1%)
- C. Guillain-Barré syndrome (30%)
- D. Malignant hyperthermia (9%)
- ✓ E. Vertebral subluxation (33%)

Omitted
Correct answer
E

33%
Answered correctly

02 secs
Time Spent

01/15/2020
Last Updated

Explanation

This patient with **rheumatoid arthritis** underwent urgent endotracheal intubation due to severe pneumonia and subsequently developed sudden-onset quadriparesis. Long-standing rheumatoid arthritis frequently involves the **cervical spine** and causes joint destruction with vertebral malalignment (**subluxation**). The atlantoaxial joint is most often involved as the atlas (C1) has a high degree of mobility relative to the axis (C2 odontoid and body).

This patient with **rheumatoid arthritis** underwent urgent endotracheal intubation due to severe pneumonia and subsequently developed sudden-onset quadriparesis. Long-standing rheumatoid arthritis frequently involves the **cervical spine** and causes joint destruction with vertebral malalignment (**subluxation**). The atlantoaxial joint is most often involved as the atlas (C1) has a high degree of mobility relative to the axis (C2 odontoid and body).

Chronic symptoms of cervical subluxation include neck pain, stiffness, and neurologic findings (eg, sensory loss, muscle weakness). **Endotracheal intubation** can **acutely worsen** the subluxation and cause **compression of the spinal cord** and/or vertebral arteries. Acute spinal cord injury results in flaccid paralysis with decreased or absent reflexes below the level of the compression due to spinal shock; the paralysis eventually becomes spastic as spinal shock resolves over the ensuing days to weeks.

(Choice A) Cerebral septic emboli are usually due to infective endocarditis of the left-sided heart valves. Patients can develop acute neurologic findings including unilateral paralysis; quadriparesis would be less likely. This patient also has no cardiac murmur or other stigmata (eg, petechiae, splinter hemorrhages) to suggest endocarditis.

(Choice B) Diabetic neuropathy presents with a slowly progressive decrease in vibratory sensation, proprioception, and temperature sensation. Early neuropathy can cause decreased ankle reflexes, whereas later disease can cause widespread loss of reflexes with motor weakness.

(Choice C) Guillain-Barré syndrome presents with progressively worsening, symmetrical, flaccid muscle weakness with absent or decreased reflexes. The abnormalities typically start in the lower extremities and ascend upward over the course of days to weeks.

(Choice D) Malignant hyperthermia is usually due to anesthesia exposure (eg, halothane, succinylcholine), causing increased and sustained muscle contraction with myocyte breakdown. Patients typically develop diffuse muscle rigidity followed by hyperthermia and possible myoglobinuria.

Educational objective:
Long-standing rheumatoid arthritis can affect the cervical spine, causing vertebral malalignment (subluxation) that can affect the atlantoaxial joint. Extension of the neck during endotracheal intubation can worsen the subluxation, leading to acute compression of the spinal cord and/or vertebral arteries.

Pathophysiology Nervous System Rheumatoid arthritis

malalignment (**subluxation**). The atlantoaxial joint is most often involved as the atlas (C1) has a high degree of mobility relative to the axis (C2 odontoid and body).

Chronic symptoms of cervical subluxation include neck pain, stiffness, and neurologic findings (eg, sensory loss, muscle weakness). **Endotracheal intubation** can **acutely worsen** the subluxation and cause **compression of the spinal cord** and/or vertebral arteries. Acute spinal cord injury results in flaccid paralysis with decreased or absent reflexes below the level of the compression due to spinal shock; the paralysis eventually becomes spastic as spinal shock resolves over the ensuing days to weeks.

(Choice A) Cerebral septic emboli are usually due to infective endocarditis of the left-sided heart valves. Patients can develop acute neurologic findings including unilateral paralysis; quadriparesis would be less likely. This patient also has no cardiac murmur or other stigmata (eg, petechiae, splinter hemorrhages) to suggest endocarditis.

(Choice B) Diabetic neuropathy presents with a slowly progressive decrease in vibratory sensation, proprioception, and temperature sensation. Early neuropathy can cause decreased ankle reflexes, whereas later disease can cause widespread loss of reflexes with motor weakness.

(Choice C) Guillain-Barré syndrome presents with progressively worsening, symmetrical, flaccid muscle weakness with absent or decreased reflexes. The abnormalities typically start in the lower extremities and ascend upward over the course of days to weeks.

(Choice D) Malignant hyperthermia is usually due to anesthesia exposure (eg, halothane, succinylcholine), causing increased and sustained muscle contraction with myocyte breakdown. Patients typically develop diffuse muscle rigidity followed by hyperthermia and possible myoglobinuria.

Educational objective:
Long-standing rheumatoid arthritis can affect the cervical spine, causing vertebral malalignment (subluxation) that can affect the atlantoaxial joint. Extension of the neck during endotracheal intubation can worsen the subluxation, leading to acute compression of the spinal cord and/or vertebral arteries.

Pathophysiology	Nervous System	Rheumatoid arthritis
Subject	System	Topic

Copyright © UWorld. All rights reserved.

A 20-year-old man comes to the office for evaluation of abnormal behavior. Over the past 4 months, the patient has had several episodes of unresponsiveness, during which he would stare blankly while smacking his lips. He spontaneously becomes responsive after about 2 minutes and has no recollection of the event. The patient says these episodes are often preceded by an uneasy sensation in his upper abdomen and the pungent smell of something burning. He has had no falls or jerky movements of the extremities. The patient has no history of recent fever, headaches, head trauma, nausea, vomiting, or focal neurologic deficit. He had seizures in early childhood precipitated by high fevers but has had none since then and reports no other medical conditions. Cranial nerve examination reveals no abnormalities. Motor strength, sensation, and deep tendon reflexes are normal throughout. Neuroimaging is most likely to reveal an abnormality in which of the following locations in the brain?

A. Cerebellar vermis

B. Hippocampus

C. Nondominant parietal lobe

D. Occipital pole

E. Premotor frontal cortex

Submit

A 20-year-old man comes to the office for evaluation of abnormal behavior. Over the past 4 months, the patient has had several episodes of unresponsiveness, during which he would stare blankly while smacking his lips. He spontaneously becomes responsive after about 2 minutes and has no recollection of the event. The patient says these episodes are often preceded by an uneasy sensation in his upper abdomen and the pungent smell of something burning. He has had no falls or jerky movements of the extremities. The patient has no history of recent fever, headaches, head trauma, nausea, vomiting, or focal neurologic deficit. He had seizures in early childhood precipitated by high fevers but has had none since then and reports no other medical conditions. Cranial nerve examination reveals no abnormalities. Motor strength, sensation, and deep tendon reflexes are normal throughout. Neuroimaging is most likely to reveal an abnormality in which of the following locations in the brain?

A. Cerebellar vermis (2%)
✓ B. Hippocampus (34%)
C. Nondominant parietal lobe (28%)
D. Occipital pole (3%)
E. Premotor frontal cortex (30%)

Omitted
Correct answer
B

34%
Answered correctly

03 secs
Time Spent

03/25/2020
Last Updated

Explanation

Focal seizures originate in a single hemisphere (vs generalized seizures, which originate throughout the cerebral cortex) and are subcategorized as:

- Focal aware seizures (previously simple partial seizure): Patients are aware and interactive but have symptoms corresponding to the

Focal seizures originate in a single hemisphere (vs generalized seizures, which originate throughout the cerebral cortex) and are subcategorized as:

- Focal aware seizures (previously simple partial seizure): Patients are aware and interactive but have symptoms corresponding to the involved area of the brain (eg, face or limb twitching/jerking - frontal lobe motor cortex, auditory/olfactory hallucinations - temporal lobe, visual phenomena - occipital lobe).
- **Focal impaired awareness seizures** (previously complex partial seizures): Patients appear awake but do not interact appropriately (eg, **blank stare**) and frequently engage in repetitive, stereotyped **automatisms** (eg, lip smacking, hand wringing, repeating words).

Focal seizures with impaired awareness are the typical manifestation of **temporal lobe epilepsy**, the most common type of recurrent seizure disorder. Seizures are often preceded by a distinctive aura (eg, **uneasy epigastric sensation**, unpleasant **olfactory hallucinations**) that localizes the origin of the epileptiform discharges to the **mesial temporal lobe** (eg, hippocampus, amygdala, parahippocampal gyrus). The disorder is usually due to underlying hippocampal sclerosis (ie, mesial temporal sclerosis), which is associated with childhood febrile seizures.

(Choice A) The cerebellar vermis is responsible for vestibular function, balance, and coordination. Although patients with temporal lobe epilepsy for several years can exhibit cerebellar atrophy with accompanying ataxia, this patient has only had seizure activity for 4 months and has no evidence of ataxia on examination.

(Choice C) The nondominant parietal lobe plays a role in nonverbal spatial mapping and orientation. A seizure affecting this part of the brain can cause distortions in a patient's sense of position (eg, a feeling of floating, changes in posture) or visual interpretation (eg, the size of objects).

(Choice D) The occipital pole contains the primary visual cortex. Seizures that originate in the occipital pole characteristically have visual auras (eg, flashing lights, visual distortions, complex hallucinations).

(Choice E) The premotor frontal cortex is responsible for the selection of movements in response to internal and external cues. A seizure affecting this part of the brain can result in abnormal posturing or repetitive movements, but abdominal and olfactory auras would not be seen.

Educational objective:
Recurrent focal impaired awareness seizures that are preceded by a distinctive aura (eg, uneasy epigastric sensation, olfactory hallucinations) are characteristic of mesial temporal lobe epilepsy. The most common etiology is hippocampal sclerosis (mesial temporal sclerosis), which is associated with childhood febrile seizures.

- Focal aware seizures (previously simple partial seizure): Patients are aware and interactive but have symptoms corresponding to the involved area of the brain (eg, face or limb twitching/jerking - frontal lobe motor cortex, auditory/olfactory hallucinations - temporal lobe, visual phenomena - occipital lobe).
- **Focal impaired awareness seizures** (previously complex partial seizures): Patients appear awake but do not interact appropriately (eg, **blank stare**) and frequently engage in repetitive, stereotyped **automatisms** (eg, lip smacking, hand wringing, repeating words).

Focal seizures with impaired awareness are the typical manifestation of **temporal lobe epilepsy**, the most common type of recurrent seizure disorder. Seizures are often preceded by a distinctive aura (eg, **uneasy epigastric sensation**, unpleasant **olfactory hallucinations**) that localizes the origin of the epileptiform discharges to the **mesial temporal lobe** (eg, hippocampus, amygdala, parahippocampal gyrus). The disorder is usually due to underlying hippocampal sclerosis (ie, mesial temporal sclerosis), which is associated with childhood febrile seizures.

(Choice A) The cerebellar vermis is responsible for vestibular function, balance, and coordination. Although patients with temporal lobe epilepsy for several years can exhibit cerebellar atrophy with accompanying ataxia, this patient has only had seizure activity for 4 months and has no evidence of ataxia on examination.

(Choice C) The nondominant parietal lobe plays a role in nonverbal spatial mapping and orientation. A seizure affecting this part of the brain can cause distortions in a patient's sense of position (eg, a feeling of floating, changes in posture) or visual interpretation (eg, the size of objects).

(Choice D) The occipital pole contains the primary visual cortex. Seizures that originate in the occipital pole characteristically have visual auras (eg, flashing lights, visual distortions, complex hallucinations).

(Choice E) The premotor frontal cortex is responsible for the selection of movements in response to internal and external cues. A seizure affecting this part of the brain can result in abnormal posturing or repetitive movements, but abdominal and olfactory auras would not be seen.

Educational objective:
Recurrent focal impaired awareness seizures that are preceded by a distinctive aura (eg, uneasy epigastric sensation, olfactory hallucinations) are characteristic of mesial temporal lobe epilepsy. The most common etiology is hippocampal sclerosis (mesial temporal sclerosis), which is associated with childhood febrile seizures.

Pathophysiology Nervous System Seizures

1
2
3
4
5
6
7
8
9
10
11
12
13
14
15
16
17
18
19
20
21
22
23
24
25
26
27
28
29

Explanation

Focal seizures originate in ... ed as:

- Focal aware seizure ... involved area of the ... visual phenomena -
- **Focal impaired aw ... blank stare**) and fre ...

Focal seizures with impair ... disorder. Seizures are oft ... localizes the origin of the ... disorder is usually due to ...

(Choice A) The cerebella ... osy for several years can exhi ... evidence of ataxia on exa ...

(Choice C) The nondomi ... can cause distortions in a pati ...

(Choice D) The occipital ... as (eg, flashing lights, visual ...

(Choice E) The premotor ... affecting this part of the brain can result in abnormal posturing or repetitive movements, but abdominal and olfactory auras would not be seen.

Educational objective:

Exhibit Display

Seizure type	Description	Preferred anticonvulsants
Focal onset (involves a single cerebral hemisphere at onset)		
Aware	• No loss of consciousness or postictal state • Motor, sensory, autonomic, or cognitive symptoms	• Carbamazepine* • Lamotrigine • Levetiracetam • Phenytoin*
Impaired awareness	• Appears awake but consciousness is altered (eg, blank stare) • Postictal state • May have automatisms (eg, lip smacking)	
Generalized onset (involves both hemispheres at onset)		
Tonic-clonic	• Loss of consciousness & postictal state • Diffuse muscle contraction of limbs (tonic) followed by rhythmic jerking (clonic)	• Levetiracetam • Valproic acid
Myoclonic	• No loss of consciousness or postictal state • Brief jerking movements	
Absence	• Brief episodes of altered consciousness (eg, blank stare) • May have automatisms • Usually no postictal state	• Ethosuxamide • Valproic acid

Add To Flash Card

Explanation

Focal seizures originate in
as:

- Focal aware seizure
involved area of the
visual phenomena -
- **Focal impaired aw**
blank stare) and fre

Focal seizures with impair
disorder. Seizures are oft
localizes the origin of the
disorder is usually due to

(Choice A) The cerebella
for several years can exhi
evidence of ataxia on exa

(Choice C) The nondomi
cause distortions in a pati

(Choice D) The occipital
(eg, flashing lights, visual

(Choice E) The premotor
affecting this part of the brain can result in abnormal posturing or repetitive movements, but abdominal and olfactory auras would not be seen.

Educational objective:

Exhibit Display

Seizure type	Description	Preferred anticonvulsants
Focal onset (involves a single cerebral hemisphere at onset)		
Aware	• No loss of consciousness or postictal state • Motor, sensory, autonomic, or cognitive symptoms	• Carbamazepine* • Lamotrigine • Levetiracetam • Phenytoin*
Impaired awareness	• Appears awake but consciousness is altered (eg, blank stare) • Postictal state • May have automatisms (eg, lip smacking)	
Generalized onset (involves both hemispheres at onset)		
Tonic-clonic	• Loss of consciousness & postictal state • Diffuse muscle contraction of limbs (tonic) followed by rhythmic jerking (clonic)	• Levetiracetam • Valproic acid
Myoclonic	• No loss of consciousness or postictal state • Brief jerking movements	
Absence	• Brief episodes of altered consciousness (eg, blank stare) • May have automatisms • Usually no postictal state	• Ethosuxamide • Valproic acid

Add To Flash Card

1
2
3
4
5
6
7
8
9
10
11
12
13
14
15
16
17
18
19
20
21
22
23
24
25
26
27
28
29

Exhibit Display

Mesial temporal sclerosis

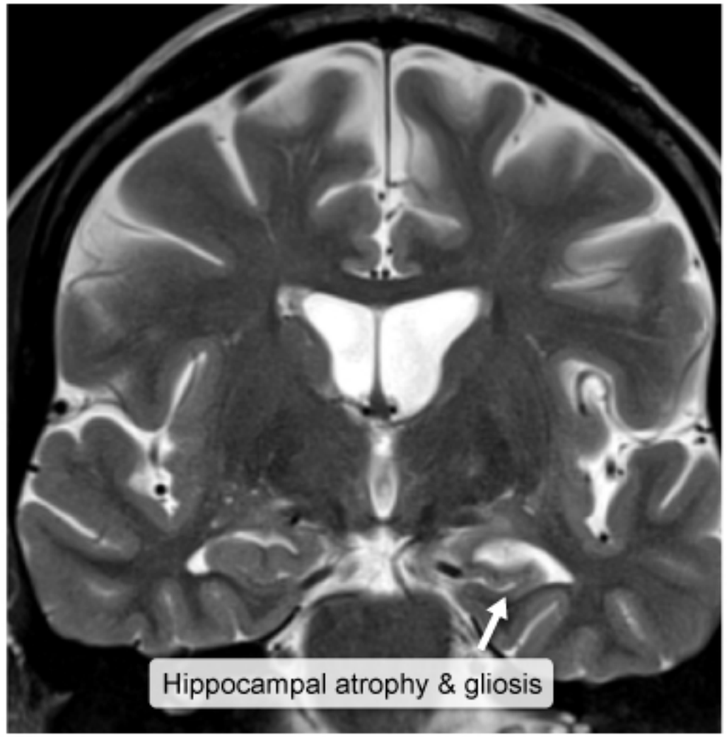

©UWorld

Zoom In
Zoom Out
Reset
Add To Flash Card

Educational objective:

- **Focal impaired awareness seizures** (previously complex partial seizures): Patients appear awake but do not interact appropriately (eg, **blank stare**) and frequently engage in repetitive, stereotyped **automatisms** (eg, lip smacking, hand wringing, repeating words).

Focal seizures with impaired awareness are the typical manifestation of **temporal lobe epilepsy**, the most common type of recurrent seizure disorder. Seizures are often preceded by a distinctive aura (eg, **uneasy epigastric sensation**, unpleasant **olfactory hallucinations**) that localizes the origin of the epileptiform discharges to the **mesial temporal lobe** (eg, hippocampus, amygdala, parahippocampal gyrus). The disorder is usually due to underlying hippocampal sclerosis (ie, mesial temporal sclerosis), which is associated with childhood febrile seizures.

(Choice A) The cerebellar vermis is responsible for vestibular function, balance, and coordination. Although patients with temporal lobe epilepsy for several years can exhibit cerebellar atrophy with accompanying ataxia, this patient has only had seizure activity for 4 months and has no evidence of ataxia on examination.

(Choice C) The nondominant parietal lobe plays a role in nonverbal spatial mapping and orientation. A seizure affecting this part of the brain can cause distortions in a patient's sense of position (eg, a feeling of floating, changes in posture) or visual interpretation (eg, the size of objects).

(Choice D) The occipital pole contains the primary visual cortex. Seizures that originate in the occipital pole characteristically have visual auras (eg, flashing lights, visual distortions, complex hallucinations).

(Choice E) The premotor frontal cortex is responsible for the selection of movements in response to internal and external cues. A seizure affecting this part of the brain can result in abnormal posturing or repetitive movements, but abdominal and olfactory auras would not be seen.

Educational objective:
Recurrent focal impaired awareness seizures that are preceded by a distinctive aura (eg, uneasy epigastric sensation, olfactory hallucinations) are characteristic of mesial temporal lobe epilepsy. The most common etiology is hippocampal sclerosis (mesial temporal sclerosis), which is associated with childhood febrile seizures.

Pathophysiology	Nervous System	Seizures
Subject	System	Topic

Copyright © UWorld. All rights reserved.

1
2
3
4
5
6
7
8
9
10
11
12
13
14
15
16
17
18
19
20
21
22
23
24
25
26
27
28
29

A study was conducted to determine the utility of adjunctive therapy in bacterial meningitis. Patients with acute bacterial meningitis whose cerebrospinal fluid (CSF) analysis showed gram-positive diplococci were divided into 2 groups. The first (control) group was given systemic antibiotics only, and the second (experimental) group was given dexamethasone followed by systemic antibiotics. Compared to the control group, patients in the experimental group developed fewer neurologic sequelae and had a lower risk of death. The experimental patients most likely benefited from the use of this drug due to which of the following?

A. Decreased cerebral metabolic activity

B. Decreased inflammatory response in the CSF

C. Increased antibiotic penetration into the CSF

D. Increased bone marrow release of neutrophils

E. Increased plasma glucose for cerebral use

Submit

1
2
3
4
5
6
7
8
9
10
11
12
13
14
15
16
17
18
19
20
21
22
23
24
25
26
27
28
29

A study was conducted to determine the utility of adjunctive therapy in bacterial meningitis. Patients with acute bacterial meningitis whose cerebrospinal fluid (CSF) analysis showed gram-positive diplococci were divided into 2 groups. The first (control) group was given systemic antibiotics only, and the second (experimental) group was given dexamethasone followed by systemic antibiotics. Compared to the control group, patients in the experimental group developed fewer neurologic sequelae and had a lower risk of death. The experimental patients most likely benefited from the use of this drug due to which of the following?

A. Decreased cerebral metabolic activity

B. Decreased inflammatory response in the CSF

C. Increased antibiotic penetration into the CSF

D. Increased bone marrow release of neutrophils

E. Increased plasma glucose for cerebral use

Submit

A study was conducted to determine the utility of adjunctive therapy in bacterial meningitis. Patients with acute bacterial meningitis whose cerebrospinal fluid (CSF) analysis showed gram-positive diplococci were divided into 2 groups. The first (control) group was given systemic antibiotics only, and the second (experimental) group was given dexamethasone followed by systemic antibiotics. Compared to the control group, patients in the experimental group developed fewer neurologic sequelae and had a lower risk of death. The experimental patients most likely benefited from the use of this drug due to which of the following?

A. Decreased cerebral metabolic activity (1%)
✓ B. Decreased inflammatory response in the CSF (83%)
C. Increased antibiotic penetration into the CSF (6%)
D. Increased bone marrow release of neutrophils (3%)
E. Increased plasma glucose for cerebral use (5%)

Omitted
Correct answer
B

83%
Answered correctly

06 secs
Time Spent

03/29/2020
Last Updated

Explanation

Acute bacterial meningitis is characterized by a massive **inflammatory response** in the central nervous system. The inflammation is driven by **bacterial subcapsular components**, particularly macromolecules of the bacterial cell wall such as teichoic acid and peptidoglycan. These components trigger the release of **inflammatory cytokines** (eg, tumor necrosis factor–alpha, interferon-gamma, interleukin 12), leading to loosening of the tight junctions of the blood-brain barrier, vasogenic edema, elevation of intracranial pressure, and recruitment of leukocytes.

Streptococcus pneumoniae, a gram-positive diplococcus, is the leading cause of acute bacterial meningitis in adults. Initial antibiotic therapy

Explanation

Acute bacterial meningitis is characterized by a massive **inflammatory response** in the central nervous system. The inflammation is driven by **bacterial subcapsular components**, particularly macromolecules of the bacterial cell wall such as teichoic acid and peptidoglycan. These components trigger the release of **inflammatory cytokines** (eg, tumor necrosis factor–alpha, interferon-gamma, interleukin 12), leading to loosening of the tight junctions of the blood-brain barrier, vasogenic edema, elevation of intracranial pressure, and recruitment of leukocytes.

Streptococcus pneumoniae, a gram-positive diplococcus, is the leading cause of acute bacterial meningitis in adults. Initial antibiotic therapy against *S pneumoniae* lyses the bacteria and releases cell wall components that increase cerebrospinal fluid (CSF) inflammatory cytokines. Studies have shown that pretreatment with **dexamethasone reduces the levels of inflammatory cytokines** in the CSF and limits risk of inflammation-induced morbidity (eg, seizures, focal neurologic deficits) and death. Other forms of bacterial meningitis, such as those due to *Neisseria meningitidis* and *Haemophilus influenzae*, do not benefit from glucocorticoid pretreatment, possibly because these gram-negative organisms have thinner cell walls (less peptidoglycan and no teichoic acid), resulting in less inflammatory cytokine release.

(Choice A) Therapeutic hypothermia (32-34 C [89.6-93.2 F]) can be used after hypoxic/ischemic brain injury due to cardiac arrest. It reduces cerebral metabolic activity and limits metabolic strain within damaged neurologic tissue. This has been shown to improve neurologic recovery and long-term outcomes.

(Choice C) The inflammatory response to bacterial components in the CSF loosens the tight junctions of the blood-brain barrier, which aids antibiotic penetration into the central nervous system. Dexamethasone reduces the inflammatory response and would be expected to decrease permeability of the blood-brain barrier.

(Choice D) Glucocorticoids promote the release of granulocytes from the bone marrow and the movement of neutrophils off the endothelial wall into the systemic circulation. This often leads to an increase in the circulating white blood cell count with delayed migration into infected tissues.

(Choice E) Glucocorticoids can cause a dose-dependent increase in fasting serum glucose levels due to stimulation of hepatic gluconeogenesis and inhibition of glucose uptake in adipose tissue.

Educational objective:
Pneumococcal meningitis is associated with massive cerebrospinal fluid inflammatory cytokine release in response to bacterial cell wall components. Treatment with dexamethasone prior to antibiotic therapy has been shown to reduce inflammation and decrease the risk of adverse outcomes (eg, seizures, focal neurologic deficits) and death. Other forms of bacterial meningitis do not seem to benefit from glucocorticoid

against *S pneumoniae* lyses the bacteria and releases cell wall components that increase cerebrospinal fluid (CSF) inflammatory cytokines. Studies have shown that pretreatment with **dexamethasone reduces the levels of inflammatory cytokines** in the CSF and limits risk of inflammation-induced morbidity (eg, seizures, focal neurologic deficits) and death. Other forms of bacterial meningitis, such as those due to *Neisseria meningitidis* and *Haemophilus influenzae*, do not benefit from glucocorticoid pretreatment, possibly because these gram-negative organisms have thinner cell walls (less peptidoglycan and no teichoic acid), resulting in less inflammatory cytokine release.

(Choice A) Therapeutic hypothermia (32-34 C [89.6-93.2 F]) can be used after hypoxic/ischemic brain injury due to cardiac arrest. It reduces cerebral metabolic activity and limits metabolic strain within damaged neurologic tissue. This has been shown to improve neurologic recovery and long-term outcomes.

(Choice C) The inflammatory response to bacterial components in the CSF loosens the tight junctions of the blood-brain barrier, which aids antibiotic penetration into the central nervous system. Dexamethasone reduces the inflammatory response and would be expected to decrease permeability of the blood-brain barrier.

(Choice D) Glucocorticoids promote the release of granulocytes from the bone marrow and the movement of neutrophils off the endothelial wall into the systemic circulation. This often leads to an increase in the circulating white blood cell count with delayed migration into infected tissues.

(Choice E) Glucocorticoids can cause a dose-dependent increase in fasting serum glucose levels due to stimulation of hepatic gluconeogenesis and inhibition of glucose uptake in adipose tissue.

Educational objective:
Pneumococcal meningitis is associated with massive cerebrospinal fluid inflammatory cytokine release in response to bacterial cell wall components. Treatment with dexamethasone prior to antibiotic therapy has been shown to reduce inflammation and decrease the risk of adverse outcomes (eg, seizures, focal neurologic deficits) and death. Other forms of bacterial meningitis do not seem to benefit from glucocorticoid treatment.

Pathophysiology	Nervous System	Meningitis
Subject	System	Topic

Copyright © UWorld. All rights reserved.

The following vignette applies to the next **2** items. The items in the set must be answered in sequential order. Once you click **Proceed to Next Item**, you will not be able to add or change an answer.

A 62-year-old woman has double vision, especially when reading at bedtime. The problem first started several months ago and was intermittent but has worsened over the last 2 weeks and now bothers her constantly. The patient has also developed difficulty chewing and swallowing foods. She usually feels better in the mornings. She has no extremity weakness or sensory symptoms. The patient has no other medical problems and takes no medications. She does not use tobacco, alcohol, or illicit drugs. Vital signs are normal. BMI is 27 kg/m^2. Examination shows bilateral ptosis; there is weakness of adduction of the right eye and abduction of the left eye. Muscle strength is 4/5 in proximal muscles in the upper and lower extremities. Deep tendon reflexes are 2+ throughout.

Item 1 of 2

Which of the following changes involving the postsynaptic muscle cell most likely explains this patient's symptoms?

- A. Impaired excitation-contraction coupling
- B. Prolonged absolute refractory period
- C. Reduced action potential amplitude
- D. Reduced action potential propagation velocity
- E. Reduced amplitude of motor end plate potential

Submit

The following vignette applies to the next **2** items. The items in the set must be answered in sequential order. Once you click **Proceed to Next Item**, you will not be able to add or change an answer.

A 62-year-old woman has double vision, especially when reading at bedtime. The problem first started several months ago and was intermittent but has worsened over the last 2 weeks and now bothers her constantly. The patient has also developed difficulty chewing and swallowing foods. She usually feels better in the mornings. She has no extremity weakness or sensory symptoms. The patient has no other medical problems and takes no medications. She does not use tobacco, alcohol, or illicit drugs. Vital signs are normal. BMI is 27 kg/m^2. Examination shows bilateral ptosis; there is weakness of adduction of the right eye and abduction of the left eye. Muscle strength is 4/5 in proximal muscles in the upper and lower extremities. Deep tendon reflexes are 2+ throughout.

Item 1 of 2

Which of the following changes involving the postsynaptic muscle cell most likely explains this patient's symptoms?

A. Impaired excitation-contraction coupling (16%)

B. Prolonged absolute refractory period (7%)

C. Reduced action potential amplitude (11%)

D. Reduced action potential propagation velocity (12%)

✓ E. Reduced amplitude of motor end plate potential (51%)

Omitted
Correct answer
E

51%
Answered correctly

01 sec
Time Spent

03/06/2020
Last Updated

1
2
3
4
5
6
7
8
9
10
11
12
13
14
15
16
17
18
19
20
21
22
23
24
25
26
27
28
29

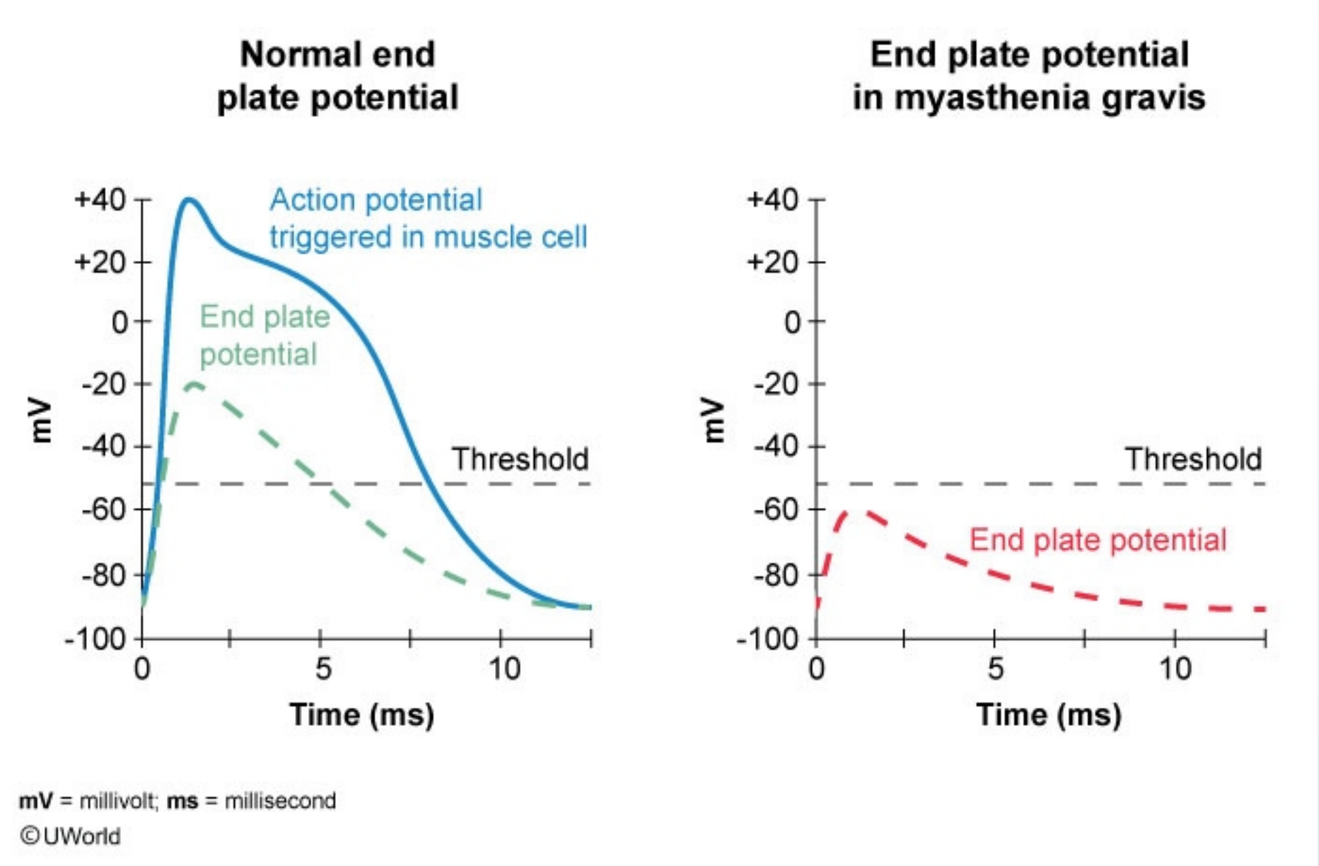

This patient with progressive diplopia and weakness with mastication (both worse at night), along with ptosis and proximal muscle weakness on examination, likely has **myasthenia gravis** (MG). This disease is characterized by:

- Fluctuating weakness of certain voluntary muscles, particularly those innervated by motor nuclei of the brainstem (eg, ocular and bulbar muscles)
- Progressive weakening over the course of the day or after exercise (fatigability)
- Decreased compound muscle action potential amplitude (the summed action potentials of all the muscle fibers in a motor unit) on electromyography with repeated excitation

1
2
3
4
5
6
7
8
9
10
11
12
13
14
15
16
17
18
19
20
21
22
23
24
25
26
27
28
29

This patient with progressive diplopia and weakness with mastication (both worse at night), along with ptosis and proximal muscle weakness on examination, likely has **myasthenia gravis** (MG). This disease is characterized by:

- Fluctuating weakness of certain voluntary muscles, particularly those innervated by motor nuclei of the brainstem (eg, ocular and bulbar muscles)
- Progressive weakening over the course of the day or after exercise (fatigability)
- Decreased compound muscle action potential amplitude (the summed action potentials of all the muscle fibers in a motor unit) on electromyography with repeated excitation
- Rapid restoration of strength of affected muscles with rest
- Improvement in strength following the administration of cholinesterase inhibitors

MG is most commonly caused by autoantibodies against postsynaptic nicotinic acetylcholine receptors. Binding of antibody to these receptors results in blockade of the receptor's active site, receptor internalization and degradation, and damage to the motor end plate due to complement fixation. Overall, this leads to **decreased numbers of functional acetylcholine receptors** at the neuromuscular junction. The decrease in the number of available cation channels reduces the end plate potential following acetylcholine release. Because the **threshold potential is not reached**, the **muscle cells do not depolarize**. Synaptic concentrations of acetylcholine are unaffected, unlike in botulism or Lambert-Eaton syndrome.

(Choice A) Excitation-contraction coupling refers to the process whereby an action potential within the muscle cell causes contraction of the muscle. In skeletal muscle, this process proceeds by the release of calcium into the cytoplasm, which subsequently binds troponin C and induces a conformational change allowing actin and myosin to bind. Impaired coupling implies that an action potential occurs but the skeletal muscle is unable to contract (eg, impaired actin and myosin binding), whereas MG is caused by a failure to achieve the threshold for an action potential to occur.

(Choice B) The absolute refractory period for muscles in patients with MG is normal.

(Choice C) The action potential amplitude of the postsynaptic muscle cell is determined by the properties of the cell membrane and is not affected by the quality of the stimulus at the muscle end plate. This is not the same as compound muscle action potential, which decreases with repeated excitation in patients with MG due to depolarization of fewer myofibers.

(Choice D) Once the threshold voltage is exceeded at the neuromuscular end plate, an action potential propagates at a velocity determined by

- Rapid restoration of strength of affected muscles with rest
- Improvement in strength following the administration of cholinesterase inhibitors

MG is most commonly caused by autoantibodies against postsynaptic nicotinic acetylcholine receptors. Binding of antibody to these receptors results in blockade of the receptor's active site, receptor internalization and degradation, and damage to the motor end plate due to complement fixation. Overall, this leads to **decreased numbers of functional acetylcholine receptors** at the neuromuscular junction. The decrease in the number of available cation channels reduces the end plate potential following acetylcholine release. Because the **threshold potential is not reached**, the **muscle cells do not depolarize**. Synaptic concentrations of acetylcholine are unaffected, unlike in botulism or Lambert-Eaton syndrome.

(Choice A) Excitation-contraction coupling refers to the process whereby an action potential within the muscle cell causes contraction of the muscle. In skeletal muscle, this process proceeds by the release of calcium into the cytoplasm, which subsequently binds troponin C and induces a conformational change allowing actin and myosin to bind. Impaired coupling implies that an action potential occurs but the skeletal muscle is unable to contract (eg, impaired actin and myosin binding), whereas MG is caused by a failure to achieve the threshold for an action potential to occur.

(Choice B) The absolute refractory period for muscles in patients with MG is normal.

(Choice C) The action potential amplitude of the postsynaptic muscle cell is determined by the properties of the cell membrane and is not affected by the quality of the stimulus at the muscle end plate. This is not the same as compound muscle action potential, which decreases with repeated excitation in patients with MG due to depolarization of fewer myofibers.

(Choice D) Once the threshold voltage is exceeded at the neuromuscular end plate, an action potential propagates at a velocity determined by the particular properties of the muscle cell membrane. In MG, the muscle cell membrane is not affected outside of the neuromuscular junction.

Educational objective:
Myasthenia gravis is an autoimmune disease that causes a decrease in the number of functional acetylcholine receptors within the neuromuscular junction. This reduces the number of postsynaptic cation channels that can open in response to acetylcholine, which reduces the amplitude of motor end plate potential and prevents muscle fiber depolarization.

Pathophysiology Nervous System Myasthenia gravis

1
2
3
4
5
6
7
8
9
10
11
12
13
14
15
16
17
18
19
20
21
22
23
24
25
26
27
28
29

- Rapid restoration of strength of affected muscles with rest

Exhibit Display

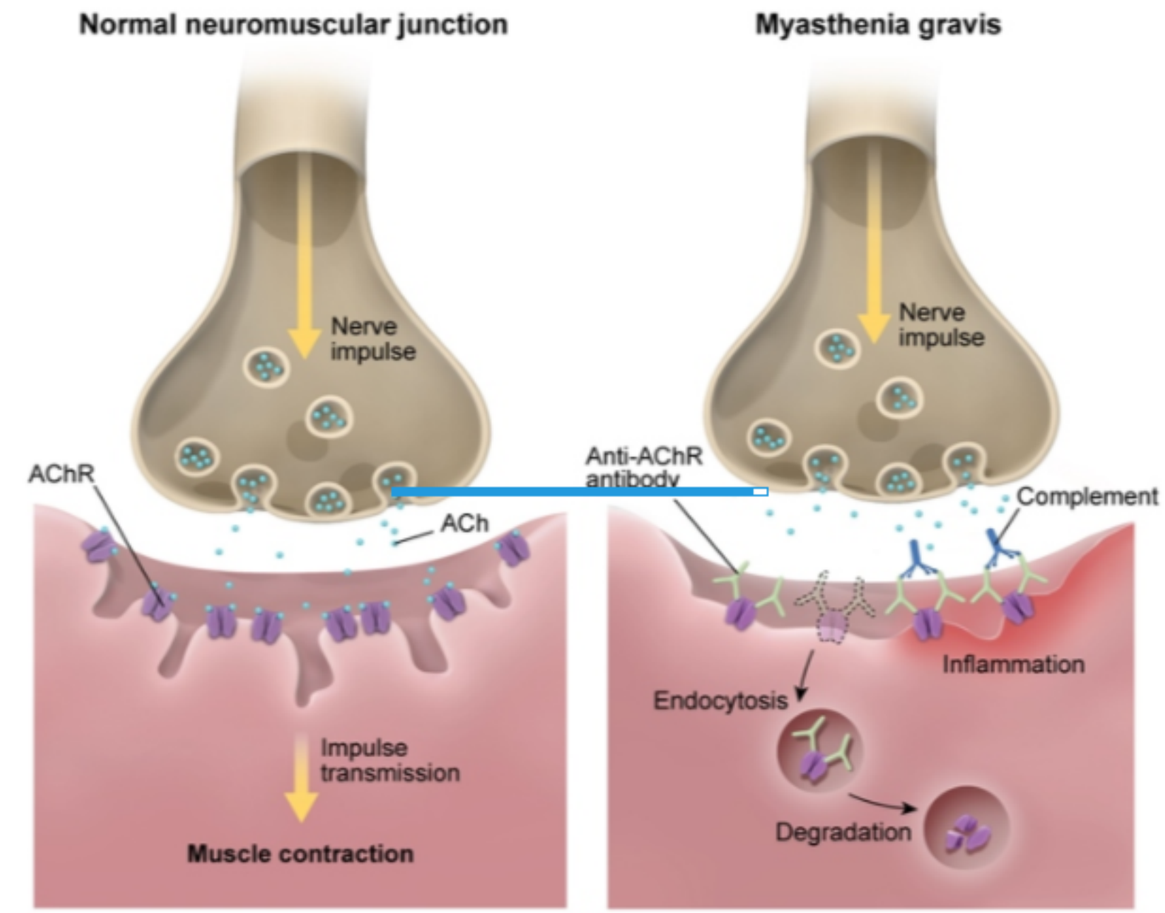

ACh = acetylcholine; AChR = acetylcholine receptor.
©UWorld

Zoom In | Zoom Out | Reset | Add To New Card | Existing Card

Pathophysiology | Nervous System | Myasthenia gravis

Item 2 of 2

The patient is started on appropriate treatment and reports significant symptom improvement. However, she now has abdominal cramping, nausea, sweating, and diarrhea. Which of the following agents can be used to effectively control these new symptoms?

A. Fluoxetine

B. Glycopyrrolate

C. Pilocarpine

D. Prazosin

E. Propranolol

Submit

Item 2 of 2

The patient is started on appropriate treatment and reports significant symptom improvement. However, she now has abdominal cramping, nausea, sweating, and diarrhea. Which of the following agents can be used to effectively control these new symptoms?

- A. Fluoxetine (4%)
- ✓ B. Glycopyrrolate (50%)
- C. Pilocarpine (31%)
- D. Prazosin (7%)
- E. Propranolol (5%)

Omitted
Correct answer
B

50%
Answered correctly

02 secs
Time Spent

03/06/2020
Last Updated

Explanation

Cholinergic toxicity	
Muscarinic effects (DUMBELS)	• Diarrhea/diaphoresis • Urination • Miosis • Bronchospasm, bronchorrhea & bradycardia • Emesis

Cholinergic toxicity	
Muscarinic effects **(DUMBELS)**	• **D**iarrhea/diaphoresis • **U**rination • **M**iosis • **B**ronchospasm, bronchorrhea & bradycardia • **E**mesis • **L**acrimation • **S**alivation
Nicotinic effects	• Muscle weakness, paralysis & fasciculations

The treatment of **myasthenia gravis** typically involves the use of a cholinesterase inhibitor, an immunosuppressive agent, and possible thymectomy. This patient is most likely receiving treatment with a **cholinesterase inhibitor**, such as pyridostigmine, which inhibits the degradation of acetylcholine in the neuromuscular junction. This improves skeletal muscle weakness but can cause **muscarinic overstimulation** of the smooth muscles and excessive glandular secretions (eg, diarrhea, diaphoresis, abdominal cramping, emesis).

Selective muscarinic antagonists (eg, glycopyrrolate, hyoscyamine, propantheline) can be used to reduce the side effects of cholinesterase inhibitors in sites where acetylcholine action is mediated by muscarinic receptors (ie, gastrointestinal tract). Because of their selectivity, these drugs improve side effects without affecting the action of cholinesterase inhibitors on skeletal muscle, which uses nicotinic receptors.

(Choice A) Fluoxetine is a selective serotonin reuptake inhibitor used primarily in the treatment of depression. It acts in a fashion similar to the cholinesterase inhibitors in that it prolongs the activity of a neurotransmitter on its target tissue. However, it is otherwise unrelated to cholinesterase inhibitors or their effects.

(Choice C) Pilocarpine is a nonselective muscarinic receptor agonist. Use of this agent would worsen this patient's side effects.

(Choices D and E) Prazosin is an alpha-1 adrenergic antagonist, and propranolol is a beta adrenergic antagonist. Use of either agent does not prevent the side effects of a cholinesterase inhibitor.

Educational objective:

1
2
3
4
5
6
7
8
9
10
11
12
13
14
15
16
17
18
19
20
21
22
23
24
25
26
27
28
29

	• Salivation
Nicotinic effects	• Muscle weakness, paralysis & fasciculations

The treatment of **myasthenia gravis** typically involves the use of a cholinesterase inhibitor, an immunosuppressive agent, and possible thymectomy. This patient is most likely receiving treatment with a **cholinesterase inhibitor**, such as pyridostigmine, which inhibits the degradation of acetylcholine in the neuromuscular junction. This improves skeletal muscle weakness but can cause **muscarinic overstimulation** of the smooth muscles and excessive glandular secretions (eg, diarrhea, diaphoresis, abdominal cramping, emesis).

Selective muscarinic antagonists (eg, glycopyrrolate, hyoscyamine, propantheline) can be used to reduce the side effects of cholinesterase inhibitors in sites where acetylcholine action is mediated by muscarinic receptors (ie, gastrointestinal tract). Because of their selectivity, these drugs improve side effects without affecting the action of cholinesterase inhibitors on skeletal muscle, which uses nicotinic receptors.

(Choice A) Fluoxetine is a selective serotonin reuptake inhibitor used primarily in the treatment of depression. It acts in a fashion similar to the cholinesterase inhibitors in that it prolongs the activity of a neurotransmitter on its target tissue. However, it is otherwise unrelated to cholinesterase inhibitors or their effects.

(Choice C) Pilocarpine is a nonselective muscarinic receptor agonist. Use of this agent would worsen this patient's side effects.

(Choices D and E) Prazosin is an alpha-1 adrenergic antagonist, and propranolol is a beta adrenergic antagonist. Use of either agent does not prevent the side effects of a cholinesterase inhibitor.

Educational objective:
The treatment of myasthenia gravis involves the use of a cholinesterase inhibitor, immunosuppressants, and possible thymectomy. Cholinesterase inhibitors may cause adverse effects related to muscarinic overstimulation, which can be ameliorated by the use of an antimuscarinic agent such as glycopyrrolate, hyoscyamine, or propantheline.

Pathophysiology	Nervous System	Myasthenia gravis
Subject	System	Topic

Copyright © UWorld. All rights reserved.

A 40-year-old man comes to the emergency department 30 minutes after experiencing a seizure. Over the past 3 months, the patient has had several episodes of brief twitching of the right hand, but today the abnormal movement gradually progressed to involve the entire right upper extremity, followed by shaking of the whole body for about a minute. He also lost consciousness and urinated involuntarily during the event. The patient feels groggy and has a mild headache. He has no other medical conditions but reports several concussions from playing football in college. Vital signs are within normal limits. Physical examination shows mild weakness of right hand grip but is otherwise normal. This patient's seizure presentation is most suggestive of which of the following etiologic processes?

A. Diffuse cerebral hypoperfusion

B. Focal structural abnormality

C. Genetic epilepsy syndrome

D. Neuroexcitatory substance use

E. Neuronal metabolic disturbance

Submit

A 40-year-old man comes to the emergency department 30 minutes after experiencing a seizure. Over the past 3 months, the patient has had several episodes of brief twitching of the right hand, but today the abnormal movement gradually progressed to involve the entire right upper extremity, followed by shaking of the whole body for about a minute. He also lost consciousness and urinated involuntarily during the event. The patient feels groggy and has a mild headache. He has no other medical conditions but reports several concussions from playing football in college. Vital signs are within normal limits. Physical examination shows mild weakness of right hand grip but is otherwise normal. This patient's seizure presentation is most suggestive of which of the following etiologic processes?

- A. Diffuse cerebral hypoperfusion (10%)
- ✓ B. Focal structural abnormality (68%)
- C. Genetic epilepsy syndrome (2%)
- D. Neuroexcitatory substance use (1%)
- E. Neuronal metabolic disturbance (16%)

Omitted
Correct answer
B

68%
Answered correctly

01 sec
Time Spent

04/07/2020
Last Updated

Explanation

This patient with prior episodes of isolated hand twitching (characteristic of focal aware seizures) now experienced a **focal-onset seizure** that progressed to a bilateral tonic-clonic seizure (previously secondarily generalized seizure) with loss of consciousness and involuntary urination.

Focal-onset seizures are caused by a regional area of hypersynchronized **excitatory neural activity** that originates in a **single hemisphere** (in contrast to generalized-onset seizures, which originate globally throughout the cerebral cortex) and are subcategorized by level of consciousness

Explanation

This patient with prior episodes of isolated hand twitching (characteristic of focal aware seizures) now experienced a **focal-onset seizure** that progressed to a bilateral tonic-clonic seizure (previously secondarily generalized seizure) with loss of consciousness and involuntary urination.

Focal-onset seizures are caused by a regional area of hypersynchronized **excitatory neural activity** that originates in a **single hemisphere** (in contrast to generalized-onset seizures, which originate globally throughout the cerebral cortex) and are subcategorized by level of consciousness during the event:

- Focal aware seizures (formerly simple partial seizures): Patients remain **aware and interactive**. Symptoms correspond to the area of brain involvement; for example, **twitching/jerking** of the face or limb **(motor cortex of frontal lobe)**, paresthesia (somatosensory cortex of parietal lobe), auditory/olfactory hallucinations (temporal lobe), or visual hallucinations (occipital lobe).
- Focal impaired awareness seizures (formerly complex partial seizures): Patients appear awake but do not interact appropriately with their environment (eg, blank stare). They frequently engage in repetitive, stereotyped actions known as automatisms (eg, lip smacking, hand wringing, repeating words).

The most common underlying cause of focal-onset seizures is a **focal structural brain abnormality** (eg, cerebral neoplasms, stroke, hippocampal sclerosis). These seizures can remain localized or **generalize** to involve both hemispheres (focal to bilateral tonic-clonic) and are frequently associated with **postictal focal neurologic deficits** (eg, this patient's right hand weakness).

(Choices A, D, and E) Diffuse cerebral hypoperfusion, neuroexcitatory substance use, and neuronal metabolic disturbances (except hyperglycemia, which can cause focal seizures) all affect the brain globally and therefore are more likely to present as a generalized seizure rather than a focal seizure. Generalized seizures are characterized by widespread and rapid propagation of neuronal hyperexcitability without the initial localizing symptoms of a focal abnormality.

(Choice C) Genetic epilepsy syndromes can have either focal seizures (eg, benign focal epilepsy of infancy) or generalized seizures (eg, Lennox-Gastaut syndrome), but these conditions typically present in childhood and persist into adulthood.

Educational objective:
Focal-onset seizures most commonly occur due to a focal structural abnormality (eg, stroke, neoplasm) that causes a region of hyperexcitable

Explanation

This patient with prior epis
progressed to a bilateral t

Focal-onset seizures are c
contrast to generalized-on
during the event:

- Focal aware seizure
involvement; for exa
parietal lobe), audit
- Focal impaired awa
environment (eg, bl
wringing, repeating

The most common underl
hippocampal sclerosis). T
frequently associated with

(Choices A, D, and E) D
hyperglycemia, which can
than a focal seizure. Gen
localizing symptoms of a f

(Choice C) Genetic epile
Gastaut syndrome), but th

Educational objective:
Focal-onset seizures most commonly occur due to a focal structural abnormality (eg, stroke, neoplasm) that causes a region of hyperexcitable

Exhibit Display

Seizure type	Description	Preferred anticonvulsants
Focal onset (involves a single cerebral hemisphere at onset)		
Aware	• No loss of consciousness or postictal state • Motor, sensory, autonomic, or cognitive symptoms	• Carbamazepine* • Lamotrigine • Levetiracetam • Phenytoin*
Impaired awareness	• Appears awake but consciousness is altered (eg, blank stare) • Postictal state • May have automatisms (eg, lip smacking)	
Generalized onset (involves both hemispheres at onset)		
Tonic-clonic	• Loss of consciousness & postictal state • Diffuse muscle contraction of limbs (tonic) followed by rhythmic jerking (clonic)	• Levetiracetam • Valproic acid
Myoclonic	• No loss of consciousness or postictal state • Brief jerking movements	
Absence	• Brief episodes of altered consciousness (eg, blank stare) • May have automatisms • Usually no postictal state	• Ethosuxamide • Valproic acid

Add To Flash Card

Explanation

This patient with prior epis
progressed to a bilateral t

Focal-onset seizures are
contrast to generalized-on
during the event:

- Focal aware seizure
involvement; for exa
parietal lobe), audit

- Focal impaired awa
environment (eg, bl
wringing, repeating

The most common underl
hippocampal sclerosis). T
frequently associated with

(Choices A, D, and E) D
hyperglycemia, which can
than a focal seizure. Gen
localizing symptoms of a f

(Choice C) Genetic epile
Gastaut syndrome), but th

Educational objective:
Focal-onset seizures most commonly occur due to a focal structural abnormality (eg, stroke, neoplasm) that causes a region of hyperexcitable

Exhibit Display

Seizure type	Description	Preferred anticonvulsants
Focal onset (involves a single cerebral hemisphere at onset)		
Aware	• No loss of consciousness or postictal state • Motor, sensory, autonomic, or cognitive symptoms	• Carbamazepine* • Lamotrigine • Levetiracetam • Phenytoin*
Impaired awareness	• Appears awake but consciousness is altered (eg, blank stare) • Postictal state • May have automatisms (eg, lip smacking)	
Generalized onset (involves both hemispheres at onset)		
Tonic-clonic	• Loss of consciousness & postictal state • Diffuse muscle contraction of limbs (tonic) followed by rhythmic jerking (clonic)	• Levetiracetam • Valproic acid
Myoclonic	• No loss of consciousness or postictal state • Brief jerking movements	
Absence	• Brief episodes of altered consciousness (eg, blank stare) • May have automatisms • Usually no postictal state	• Ethosuxamide • Valproic acid

Add To Flash Card

- Focal aware seizures (formerly simple partial seizures): Patients remain **aware and interactive**. Symptoms correspond to the area of brain involvement; for example, **twitching/jerking** of the face or limb **(motor cortex of frontal lobe)**, paresthesia (somatosensory cortex of parietal lobe), auditory/olfactory hallucinations (temporal lobe), or visual hallucinations (occipital lobe).
- Focal impaired awareness seizures (formerly complex partial seizures): Patients appear awake but do not interact appropriately with their environment (eg, blank stare). They frequently engage in repetitive, stereotyped actions known as automatisms (eg, lip smacking, hand wringing, repeating words).

The most common underlying cause of focal-onset seizures is a **focal structural brain abnormality** (eg, cerebral neoplasms, stroke, hippocampal sclerosis). These seizures can remain localized or **generalize** to involve both hemispheres (focal to bilateral tonic-clonic) and are frequently associated with **postictal focal neurologic deficits** (eg, this patient's right hand weakness).

(Choices A, D, and E) Diffuse cerebral hypoperfusion, neuroexcitatory substance use, and neuronal metabolic disturbances (except hyperglycemia, which can cause focal seizures) all affect the brain globally and therefore are more likely to present as a generalized seizure rather than a focal seizure. Generalized seizures are characterized by widespread and rapid propagation of neuronal hyperexcitability without the initial localizing symptoms of a focal abnormality.

(Choice C) Genetic epilepsy syndromes can have either focal seizures (eg, benign focal epilepsy of infancy) or generalized seizures (eg, Lennox-Gastaut syndrome), but these conditions typically present in childhood and persist into adulthood.

Educational objective:
Focal-onset seizures most commonly occur due to a focal structural abnormality (eg, stroke, neoplasm) that causes a region of hyperexcitable neuronal activity in one cerebral hemisphere. These seizures begin with localized symptomatology (eg, muscle twitching, paresthesia) and are classified according to level of consciousness (eg, aware, impaired awareness). They can progress to bilateral tonic-clonic seizures if the excitatory neuronal activity spreads to involve both cerebral hemispheres.

Pathophysiology	Nervous System	Seizures
Subject	System	Topic

Copyright © UWorld. All rights reserved.

1
2
3
4
5
6
7
8
9
10
11
12
13
14
15
16
17
18
19
20
21
22
23
24
25
26
27
28
29

A 14-year-old, previously healthy girl is brought to the office due to recurrent headaches. The patient has had 4 episodes of severe, throbbing pain on the right side of her head over the last 2 months, with the most recent occurring a week ago. The headaches are often associated with nausea, and the patient has had occasional vomiting. Lying in a dark room and taking acetaminophen improve the pain. The episodes resolve after 4-5 hours. The patient has had no visual disturbances or focal weakness but has tingling and numbness on the right upper extremity prior to the headaches. Vital signs are within normal limits. Physical examination, including funduscopic and neurologic examination, shows no abnormalities. Which of the following is most likely involved in the pathogenesis of this patient's current condition?

A. Adrenal medullary catecholamines

B. Astrocyte epidermal growth factor receptors

C. Hypothalamic orexin A and B peptides

D. Thalamocortical fiber calcium channels

E. Trigeminal calcitonin gene-related peptides

Submit

A 14-year-old, previously healthy girl is brought to the office due to recurrent headaches. The patient has had 4 episodes of severe, throbbing pain on the right side of her head over the last 2 months, with the most recent occurring a week ago. The headaches are often associated with nausea, and the patient has had occasional vomiting. Lying in a dark room and taking acetaminophen improve the pain. The episodes resolve after 4-5 hours. The patient has had no visual disturbances or focal weakness but has tingling and numbness on the right upper extremity prior to the headaches. Vital signs are within normal limits. Physical examination, including funduscopic and neurologic examination, shows no abnormalities. Which of the following is most likely involved in the pathogenesis of this patient's current condition?

- A. Adrenal medullary catecholamines (3%)
- B. Astrocyte epidermal growth factor receptors (2%)
- C. Hypothalamic orexin A and B peptides (6%)
- D. Thalamocortical fiber calcium channels (14%)
- ✓ E. Trigeminal calcitonin gene-related peptides (73%)

Omitted
Correct answer
E

73%
Answered correctly

01 min, 35 secs
Time Spent

05/06/2020
Last Updated

Explanation

Migraine pathogenesis & triptan mechanism of action

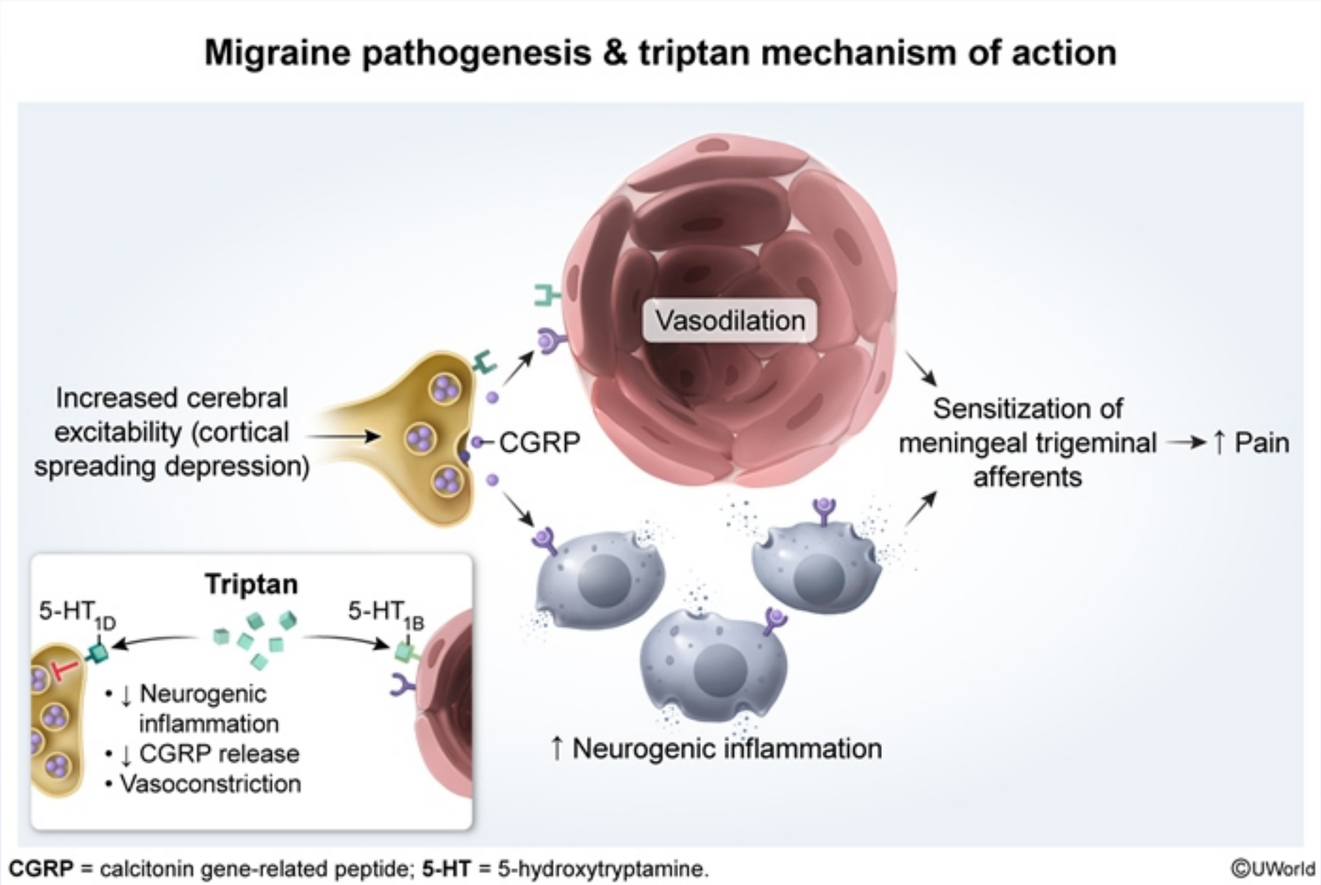

This patient with a normal neurologic examination has episodic, throbbing, **unilateral headaches** associated with **nausea**, vomiting, and **light sensitivity**; findings characteristic of **migraines**. An **aura** may precede the headache in some patients and is most commonly visual (eg, scotoma) or sensory (eg, unilateral extremity paresthesia).

The pathogenesis of migraines is multifactorial with a genetic predisposition to **increased cerebral excitability**, allowing a wave of **cortical spreading depression** to propagate across the cerebral cortex. Cortical spreading depression is likely involved in generating the pre-migraine **aura** and is associated with the abnormal activation of **trigeminal afferents**, which extend to the meninges and intracranial vasculature. This

CGRP = calcitonin gene-related peptide; **5-HT** = 5-hydroxytryptamine.

©UWorld

This patient with a normal neurologic examination has episodic, throbbing, **unilateral headaches** associated with **nausea**, vomiting, and **light sensitivity**; findings characteristic of **migraines**. An **aura** may precede the headache in some patients and is most commonly visual (eg, scotoma) or sensory (eg, unilateral extremity paresthesia).

The pathogenesis of migraines is multifactorial with a genetic predisposition to **increased cerebral excitability**, allowing a wave of **cortical spreading depression** to propagate across the cerebral cortex. Cortical spreading depression is likely involved in generating the pre-migraine **aura** and is associated with the abnormal activation of **trigeminal afferents**, which extend to the meninges and intracranial vasculature. This activation results in the release of **calcitonin gene-related peptide** (CGRP), a neuropeptide involved in **pain transmission**. CGRP also causes local vasodilation and increased neurogenic inflammation, which can further sensitize trigeminal afferents and increase pain.

The role of CGRP in migraine pathogenesis has been supported by the effectiveness of triptans ([5-$HT_{1B/1D}$] receptor agonists that decrease CGRP release) and anti-CGRP antibodies (eg, erenumab) in treating migraine headaches.

(Choice A) Pheochromocytoma is a catecholamine-producing adrenal medullary tumor that causes brief (<1 hr) episodic headaches associated with sweating, palpitations, and hypertension (rather than an aura).

(Choice B) Amplification of epidermal growth factor receptors is associated with the development of astrocytoma and glioblastoma. Headache and vomiting due to increased intracranial pressure are common but typically associated with other neurologic manifestations (eg, seizures, focal neurologic deficits).

(Choice C) Orexin A and B are excitatory neuropeptides that are produced in the lateral hypothalamus during wakefulness and inhibit the transition to REM sleep. Instead of episodic headaches, deficiency of these neuropeptides causes the daytime sleepiness, inappropriate bouts of REM sleep (ie, sleep attacks), and emotionally triggered transient muscle weakness (ie, cataplexy) seen in narcolepsy.

(Choice D) Dysfunction of the thalamocortical fiber calcium channels can contribute to the development of absence seizures, which are brief (10-20 sec) staring episodes with impairment of consciousness, not recurrent headaches.

Educational objective:
Migraines are episodic, unilateral, throbbing headaches associated with nausea, vomiting, and sensitivity to light. The pathogenesis of migraines involves a genetic predisposition to increased cerebral excitability (eg, cortical spreading depression), which leads to abnormal neuronal activation of trigeminal afferents and the release of calcitonin gene-related peptide, a vasoactive neuropeptide involved in the transmission of pain signals.

local vasodilation and increased neurogenic inflammation, which can further sensitize trigeminal afferents and increase pain.

The role of CGRP in migraine pathogenesis has been supported by the effectiveness of triptans ([5-$HT_{1B/1D}$] receptor agonists that decrease CGRP release) and anti-CGRP antibodies (eg, erenumab) in treating migraine headaches.

(Choice A) Pheochromocytoma is a catecholamine-producing adrenal medullary tumor that causes brief (<1 hr) episodic headaches associated with sweating, palpitations, and hypertension (rather than an aura).

(Choice B) Amplification of epidermal growth factor receptors is associated with the development of astrocytoma and glioblastoma. Headache and vomiting due to increased intracranial pressure are common but typically associated with other neurologic manifestations (eg, seizures, focal neurologic deficits).

(Choice C) Orexin A and B are excitatory neuropeptides that are produced in the lateral hypothalamus during wakefulness and inhibit the transition to REM sleep. Instead of episodic headaches, deficiency of these neuropeptides causes the daytime sleepiness, inappropriate bouts of REM sleep (ie, sleep attacks), and emotionally triggered transient muscle weakness (ie, cataplexy) seen in narcolepsy.

(Choice D) Dysfunction of the thalamocortical fiber calcium channels can contribute to the development of absence seizures, which are brief (10-20 sec) staring episodes with impairment of consciousness, not recurrent headaches.

Educational objective:
Migraines are episodic, unilateral, throbbing headaches associated with nausea, vomiting, and sensitivity to light. The pathogenesis of migraines involves a genetic predisposition to increased cerebral excitability (eg, cortical spreading depression), which leads to abnormal neuronal activation of trigeminal afferents and the release of calcitonin gene-related peptide, a vasoactive neuropeptide involved in the transmission of pain signals.

References

- The trigeminovascular pathway: role of CGRP and CGRP receptors in migraine.
- An update on migraine: current understanding and future directions.

Pathophysiology	Nervous System	Migraine
Subject	System	Topic

Copyright © UWorld. All rights reserved.

1
2
3
4
5
6
7
8
9
10
11
12
13
14
15
16
17
18
19
20
21
22
23
24
25
26
27
28
29

A 75-year-old man comes to the office due to a 2-year history of slowly worsening vision in both eyes. The symptoms are worse at night and the patient has stopped driving at night due to excessive glare from oncoming headlights. He has worked his entire life as a farmer and continues to drive tractors and other farm equipment during the day without difficulty. Medical history is unremarkable. Ocular examination shows loss of the red reflex and poor visualization of retinal detail. Acuity testing shows 20/100 vision in both eyes; visual field testing is normal. Which of the following is the most likely etiologic factor for this patient's eye condition?

A. Accumulation of sorbitol in the lens

B. Age-related oxidative injury

C. Decreased collagen fibril production

D. Ischemia and neovascularization

E. Loss of lens distensibility

Submit

A 75-year-old man comes to the office due to a 2-year history of slowly worsening vision in both eyes. The symptoms are worse at night and the patient has stopped driving at night due to excessive glare from oncoming headlights. He has worked his entire life as a farmer and continues to drive tractors and other farm equipment during the day without difficulty. Medical history is unremarkable. Ocular examination shows loss of the red reflex and poor visualization of retinal detail. Acuity testing shows 20/100 vision in both eyes; visual field testing is normal. Which of the following is the most likely etiologic factor for this patient's eye condition?

- A. Accumulation of sorbitol in the lens (21%)
- ✓ B. Age-related oxidative injury (55%)
- C. Decreased collagen fibril production (3%)
- D. Ischemia and neovascularization (4%)
- E. Loss of lens distensibility (14%)

Omitted
Correct answer
B

55%
Answered correctly

02 secs
Time Spent

05/07/2020
Last Updated

Explanation

Clinical features of age-related cataract	
Risk factors	• Age >60 • Chronic sunlight exposure • Diabetes mellitus

Clinical features of age-related cataract	
Risk factors	• Age >60 • Chronic sunlight exposure • Diabetes mellitus • Glucocorticoid use • Smoking • HIV infection
Symptoms	• Gradual loss of visual acuity • Excessive glare, halos around bright lights • Myopic shift
Signs	• Opacification of lens • Loss of red reflex

This patient has **cataracts**: progressive opacification of the lenses with chronic **loss of visual acuity**. Scattering of light within the lens leads to glare and halos around bright lights, especially at night. Examination reveals cloudiness in the lens, decreased detail when examining the retina, and loss of the red reflex.

Transparency of the lens requires an ordered epithelial cell structure and maintenance of intracellular crystallins. **Aging** and environmental stressors can disrupt transparency and contribute to cataract formation through the following mechanisms:

- **Nuclear sclerosis**: new layers of epithelia form on the cortex of the lens, compacting older layers beneath
- **Photooxidative damage** and cross-linking of crystallins causes brown/yellow pigmentary changes
- **Osmotic injury** resulting in development of hydropic lens fibers that degenerate

Cumulative photooxidative stress is worsened by heavy **UV exposure** (eg, outdoor occupations), smoking, or ionizing radiation. Likewise, osmotic injury is accelerated in patients with diabetes mellitus. A disordered balance of prooxidative versus antioxidative compounds in the lens (eg, decreased glutathione) may also contribute.

Signs	• Opacification of lens • Loss of red reflex

This patient has **cataracts**: progressive opacification of the lenses with chronic **loss of visual acuity**. Scattering of light within the lens leads to glare and halos around bright lights, especially at night. Examination reveals cloudiness in the lens, decreased detail when examining the retina, and loss of the red reflex.

Transparency of the lens requires an ordered epithelial cell structure and maintenance of intracellular crystallins. **Aging** and environmental stressors can disrupt transparency and contribute to cataract formation through the following mechanisms:

- **Nuclear sclerosis**: new layers of epithelia form on the cortex of the lens, compacting older layers beneath
- **Photooxidative damage** and cross-linking of crystallins causes brown/yellow pigmentary changes
- **Osmotic injury** resulting in development of hydropic lens fibers that degenerate

Cumulative photooxidative stress is worsened by heavy **UV exposure** (eg, outdoor occupations), smoking, or ionizing radiation. Likewise, osmotic injury is accelerated in patients with diabetes mellitus. A disordered balance of prooxidative versus antioxidative compounds in the lens (eg, decreased glutathione) may also contribute.

(Choice A) In patients with diabetes, excess glucose is converted to sorbitol at a greater rate than sorbitol can be metabolized to fructose. Osmotic injury due to the higher concentration of sorbitol in the lens can lead to cataract. However, in patients without diabetes, the conversion of sorbitol to fructose is adequate to prevent the buildup of sorbitol.

(Choice C) Photoaging of skin is characterized by decreased collagen fibril production and loss of tissue elasticity in sun-exposed areas. However, defects in collagen production are not a significant contributor to cataract.

(Choice D) Microvascular ischemia in patients with long-standing diabetes can cause neovascularization in the retina, leading to diabetic retinopathy. Most patients are asymptomatic until late in the course of the disease, when vitreous hemorrhage or retinal detachment causes acute vision loss.

(Choice E) Presbyopia is a type of refractive error caused by loss of the normal distensibility of the lens with age. It reduces the ability of the eye to focus on near objects but does not cause loss of visual acuity.

glare and halos around bright lights, especially at night. Examination reveals cloudiness in the lens, decreased detail when examining the retina,

Exhibit Display

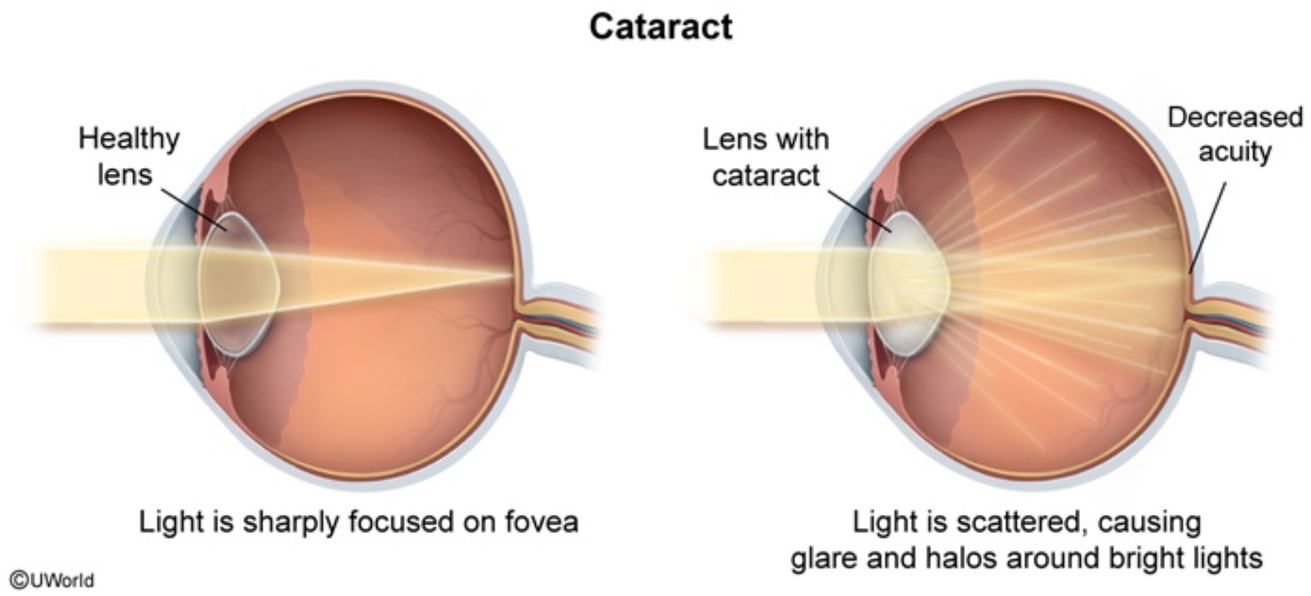

Zoom In Zoom Out Reset Add To Flash Card

glare and halos around bright lights, especially at night. Examination reveals cloudiness in the lens, decreased detail when examining the retina,

Exhibit Display

Normal eyes & white reflex

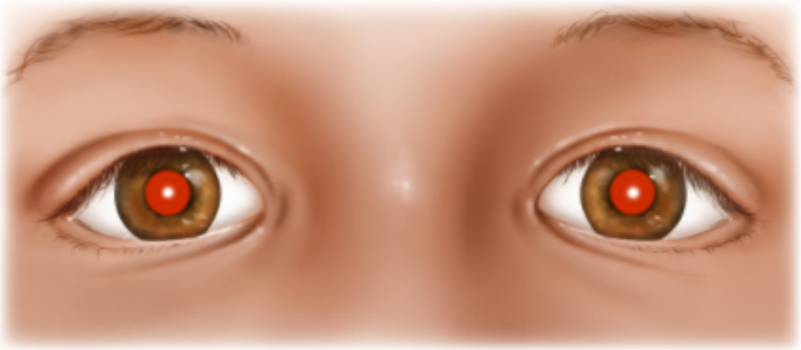

Normal eyes
Red reflexes & corneal light reflexes are equal.

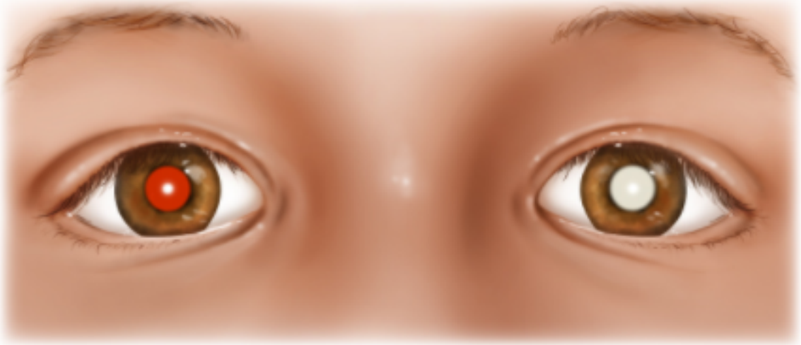

Absent reflex
White reflex on abnormal eye can result from opacities of the lens (eg, cataract) or tumor (eg, retinoblastoma).

©UWorld

Zoom In
Zoom Out
Reset
Add To Flash Card

glare and halos around bright lights, especially at night. Examination reveals cloudiness in the lens, decreased detail when examining the retina,

Exhibit Display

Normal eyes & white reflex

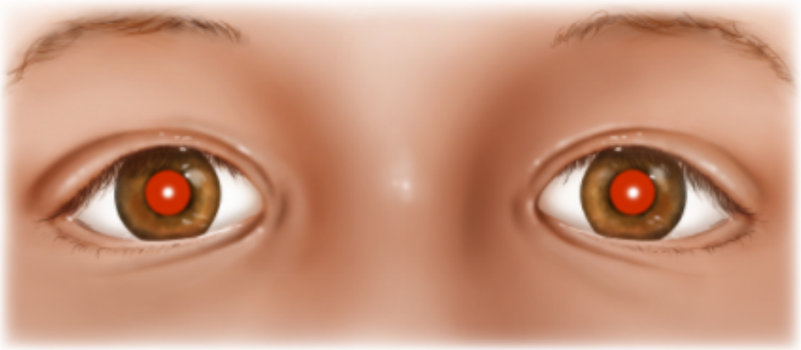

Normal eyes
Red reflexes & corneal light reflexes are equal.

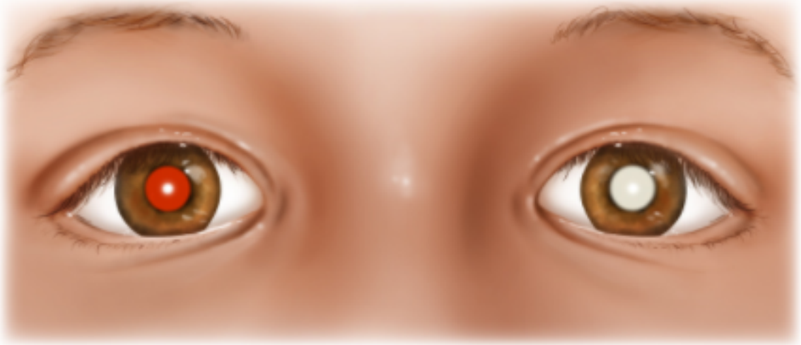

Absent reflex
White reflex on abnormal eye can result from opacities of the lens (eg, cataract) or tumor (eg, retinoblastoma).

©UWorld

Zoom In
Zoom Out
Reset
Add To Flash Card

- **Osmotic injury** resulting in development of hydropic lens fibers that degenerate

Cumulative photooxidative stress is worsened by heavy **UV exposure** (eg, outdoor occupations), smoking, or ionizing radiation. Likewise, osmotic injury is accelerated in patients with diabetes mellitus. A disordered balance of prooxidative versus antioxidative compounds in the lens (eg, decreased glutathione) may also contribute.

(Choice A) In patients with diabetes, excess glucose is converted to sorbitol at a greater rate than sorbitol can be metabolized to fructose. Osmotic injury due to the higher concentration of sorbitol in the lens can lead to cataract. However, in patients without diabetes, the conversion of sorbitol to fructose is adequate to prevent the buildup of sorbitol.

(Choice C) Photoaging of skin is characterized by decreased collagen fibril production and loss of tissue elasticity in sun-exposed areas. However, defects in collagen production are not a significant contributor to cataract.

(Choice D) Microvascular ischemia in patients with long-standing diabetes can cause neovascularization in the retina, leading to diabetic retinopathy. Most patients are asymptomatic until late in the course of the disease, when vitreous hemorrhage or retinal detachment causes acute vision loss.

(Choice E) Presbyopia is a type of refractive error caused by loss of the normal distensibility of the lens with age. It reduces the ability of the eye to focus on near objects but does not cause loss of visual acuity.

Educational objective:
Cataracts are characterized by progressive opacification of the lens with chronic loss of visual acuity. Aging and environmental exposures (eg, UV light) contribute to cataract formation by inducing nuclear sclerosis, photooxidative damage to lens crystallins, and osmotic injury.

References

- Etiopathogenesis of cataract: an appraisal.

Pathophysiology	Ophthalmology	Cataract
Subject	System	Topic

Copyright © UWorld. All rights reserved.

1
2
3
4
5
6
7
8
9
10
11
12
13
14
15
16
17
18
19
20
21
22
23
24
25
26
27
28
29

A 62-year-old man comes to the office with his wife due to behavioral changes. The patient has become increasingly impulsive and irritable over the past 1-2 years. He recently lost his job after making inappropriate comments and touching female coworkers. The patient has also lost interest in his hobbies and appears withdrawn during social gatherings. His other medical problems are hypertension and hyperlipidemia. A thorough neuropsychological assessment is conducted. Inability to perform which of the following tasks would be most indicative of frontal lobe dysfunction?

A. Comprehending the meaning of a sentence

B. Describing similarities between a watch and a ruler

C. Differentiating between right and left

D. Identifying which finger is touched

E. Recognizing familiar faces

Submit

A 62-year-old man comes to the office with his wife due to behavioral changes. The patient has become increasingly impulsive and irritable over the past 1-2 years. He recently lost his job after making inappropriate comments and touching female coworkers. The patient has also lost interest in his hobbies and appears withdrawn during social gatherings. His other medical problems are hypertension and hyperlipidemia. A thorough neuropsychological assessment is conducted. Inability to perform which of the following tasks would be most indicative of frontal lobe dysfunction?

- A. Comprehending the meaning of a sentence (17%)
- ✓ B. Describing similarities between a watch and a ruler (59%)
- C. Differentiating between right and left (4%)
- D. Identifying which finger is touched (2%)
- E. Recognizing familiar faces (16%)

Omitted
Correct answer
B

59%
Answered correctly

01 sec
Time Spent

03/01/2020
Last Updated

Explanation

The **frontal lobes** are involved in a wide array of functions, including **personality**, **language**, **motor functions**, and **executive functions**. Executive functions include **abstraction**, planning, impulse inhibition, attention, and working memory. Abstraction may be tested by asking a patient to describe the similarities between two objects (eg, a watch and ruler both measure things). Patients with frontal lobe damage may be unable to provide an answer or may provide concrete answers such as "they both have numbers."

Because of its role in personality and impulse inhibition, processes that damage the frontal lobe (eg, traumatic brain injury, frontotemporal

1
2
3
4
5
6
7
8
9
10
11
12
13
14
15
16
17
18
19
20
21
22
23
24
25
26
27
28
29

A 4-year-old boy is brought to the emergency department by his parents following a seizure. The patient has had an upper respiratory illness for the last 2 days but has no previous history of seizures. Today, he suddenly became unresponsive and his arms and legs started shaking for approximately 40 seconds. The patient was alert when the paramedics arrived at his house. In the emergency department, temperature is 40 C (104 F) and pulse is 110/min. The patient appears tired but is alert and cooperative. Physical examination shows clear nasal discharge and mild pharyngeal erythema but no nuchal rigidity or other neurologic deficits. Which of the following is the most likely underlying cause of this patient's seizure?

A. Hyperthermia-induced diffuse neuronal dysfunction

B. Microbial invasion of the meningeal layers

C. Neuronal injury from cross-reacting antiviral antibodies

D. Severe neuronal loss and gliosis in the hippocampus

E. Synchronized discharge of thalamocortical tracts

Submit

A 4-year-old boy is brought to the emergency department by his parents following a seizure. The patient has had an upper respiratory illness for the last 2 days but has no previous history of seizures. Today, he suddenly became unresponsive and his arms and legs started shaking for approximately 40 seconds. The patient was alert when the paramedics arrived at his house. In the emergency department, temperature is 40 C (104 F) and pulse is 110/min. The patient appears tired but is alert and cooperative. Physical examination shows clear nasal discharge and mild pharyngeal erythema but no nuchal rigidity or other neurologic deficits. Which of the following is the most likely underlying cause of this patient's seizure?

- ✓ A. Hyperthermia-induced diffuse neuronal dysfunction (81%)
- B. Microbial invasion of the meningeal layers (4%)
- C. Neuronal injury from cross-reacting antiviral antibodies (8%)
- D. Severe neuronal loss and gliosis in the hippocampus (0%)
- E. Synchronized discharge of thalamocortical tracts (5%)

Omitted
Correct answer
A

81%
Answered correctly

02 secs
Time Spent

04/20/2020
Last Updated

Explanation

Febrile seizure	
Risk factors	• High fever (typically due to viral illness) • Family history of seizures

A 62-year-old man comes to the office with his wife due to behavioral changes. The patient has become increasingly impulsive and irritable over the past 1-2 years. He recently lost his job after making inappropriate comments and touching female coworkers. The patient has also lost interest in his hobbies and appears withdrawn during social gatherings. His other medical problems are hypertension and hyperlipidemia. A thorough neuropsychological assessment is conducted. Inability to perform which of the following tasks would be most indicative of frontal lobe dysfunction?

- A. Comprehending the meaning of a sentence (17%)
- ✓ B. Describing similarities between a watch and a ruler (59%)
- C. Differentiating between right and left (4%)
- D. Identifying which finger is touched (2%)
- E. Recognizing familiar faces (16%)

Omitted
Correct answer
B

59%
Answered correctly

01 sec
Time Spent

03/01/2020
Last Updated

Explanation

The **frontal lobes** are involved in a wide array of functions, including **personality**, **language**, **motor functions**, and **executive functions**. Executive functions include **abstraction**, planning, impulse inhibition, attention, and working memory. Abstraction may be tested by asking a patient to describe the similarities between two objects (eg, a watch and ruler both measure things). Patients with frontal lobe damage may be unable to provide an answer or may provide concrete answers such as "they both have numbers."

Because of its role in personality and impulse inhibition, processes that damage the frontal lobe (eg, traumatic brain injury, frontotemporal

Explanation

The **frontal lobes** are involved in a wide array of functions, including **personality**, **language**, **motor functions**, and **executive functions**. Executive functions include **abstraction**, planning, impulse inhibition, attention, and working memory. Abstraction may be tested by asking a patient to describe the similarities between two objects (eg, a watch and ruler both measure things). Patients with frontal lobe damage may be unable to provide an answer or may provide concrete answers such as "they both have numbers."

Because of its role in personality and impulse inhibition, processes that damage the frontal lobe (eg, traumatic brain injury, frontotemporal dementia) may lead to significant changes in behavior. Behavior change is more likely with bilateral, rather than unilateral, injury. Patients with frontal lobe injury may be disinhibited, socially inappropriate, irritable, and impulsive.

(Choice A) Impaired language comprehension (ie, Wernicke aphasia) results from lesions in the dominant superior temporal gyrus.

(Choices C and D) Patients with lesions in the dominant angular and supramarginal gyri (located in the parietal lobe) may have right-left disorientation and finger agnosia (ie, inability to recognize fingers). When these symptoms are accompanied by agraphia (ie, inability to write) and acalculia (ie, inability to perform arithmetic), it is known as Gerstmann syndrome.

(Choice E) The inability to recognize a familiar face (ie, prosopagnosia) may result from lesions in the fusiform gyrus (located in the temporal and occipital lobes).

Educational objective:
The frontal lobes are involved in personality, language, motor functions, and executive functions (eg, abstraction). Frontal lobe function may be diagnosed by testing abstraction ability (eg, asking about the similarities between two related objects) on the mental status examination.

References

- Why do patients with neurodegenerative frontal syndrome fail to answer: 'In what way are an orange and a banana alike?'

Pathophysiology	Nervous System	Frontotemporal dementia
Subject	System	Topic

Copyright © UWorld. All rights reserved.

1
2
3
4
5
6
7
8
9
10
11
12
13
14
15
16
17
18
19
20
21
22
23
24
25
26
27
28
29

A 4-year-old boy is brought to the emergency department by his parents following a seizure. The patient has had an upper respiratory illness for the last 2 days but has no previous history of seizures. Today, he suddenly became unresponsive and his arms and legs started shaking for approximately 40 seconds. The patient was alert when the paramedics arrived at his house. In the emergency department, temperature is 40 C (104 F) and pulse is 110/min. The patient appears tired but is alert and cooperative. Physical examination shows clear nasal discharge and mild pharyngeal erythema but no nuchal rigidity or other neurologic deficits. Which of the following is the most likely underlying cause of this patient's seizure?

A. Hyperthermia-induced diffuse neuronal dysfunction

B. Microbial invasion of the meningeal layers

C. Neuronal injury from cross-reacting antiviral antibodies

D. Severe neuronal loss and gliosis in the hippocampus

E. Synchronized discharge of thalamocortical tracts

A 4-year-old boy is brought to the emergency department by his parents following a seizure. The patient has had an upper respiratory illness for the last 2 days but has no previous history of seizures. Today, he suddenly became unresponsive and his arms and legs started shaking for approximately 40 seconds. The patient was alert when the paramedics arrived at his house. In the emergency department, temperature is 40 C (104 F) and pulse is 110/min. The patient appears tired but is alert and cooperative. Physical examination shows clear nasal discharge and mild pharyngeal erythema but no nuchal rigidity or other neurologic deficits. Which of the following is the most likely underlying cause of this patient's seizure?

- ✓ A. Hyperthermia-induced diffuse neuronal dysfunction (81%)
- B. Microbial invasion of the meningeal layers (4%)
- C. Neuronal injury from cross-reacting antiviral antibodies (8%)
- D. Severe neuronal loss and gliosis in the hippocampus (0%)
- E. Synchronized discharge of thalamocortical tracts (5%)

Omitted
Correct answer
A

81%
Answered correctly

04 secs
Time Spent

04/20/2020
Last Updated

Explanation

Febrile seizure	
Risk factors	• High fever (typically due to viral illness) • Family history of seizures

Febrile seizure	
Risk factors	• High fever (typically due to viral illness) • Family history of seizures
Pathophysiology	• Circulating cytokines • Hyperthermia-induced diffuse neuronal dysfunction
Diagnostic criteria	• Age 6 months to 5 years • No previous afebrile seizure • Absence of CNS infection/inflammation • Absence of a potential metabolic cause (eg, hypoglycemia)
Management	• Symptomatic care (eg, antipyretics) • Abortive therapy (if ≥5 min) • Reassurance

This patient's presentation is consistent with **febrile seizure**, a generally **benign** neurologic condition characterized by seizure and elevated temperature (≥38 C [100.4 F]) without signs of CNS infection (eg, nuchal rigidity) or metabolic abnormality. Children age **6 months to 5 years** are almost exclusively affected because seizure threshold is lower during early years of brain development. In addition, young children are particularly susceptible to febrile **viral illnesses** (eg, roseola, influenza) associated with **high fever** (≥39.5 C [103 F]), a key risk factor for development of seizures due to **hyperthermia-induced neuronal dysfunction**.

A simple febrile seizure is characterized by a generalized seizure (eg, unresponsiveness, tonic-clonic movements) that is short (<15 min) and does not recur within 24 hours. Benzodiazepines can be used to abort seizures lasting ≥5 mins; however, most self-resolve prior to presentation. Treatment primarily involves **antipyretics** (eg, nonsteroidal anti-inflammatory drugs), which **decrease fever** by inhibiting prostaglandin E_2 synthesis and counteracting the effects of circulating cytokines, resulting in reduction of the thermoregulatory set point in the hypothalamus.

(Choice B) Microbial invasion of the meningeal layers occurs with meningitis, a serious infection that may progress to encephalitis and trigger generalized seizures. However, meningitis causes other findings not seen in this patient, such as nausea/vomiting, photophobia, nuchal rigidity,

This patient's presentation is consistent with **febrile seizure**, a generally **benign** neurologic condition characterized by seizure and elevated temperature (≥38 C [100.4 F]) without signs of CNS infection (eg, nuchal rigidity) or metabolic abnormality. Children age **6 months to 5 years** are almost exclusively affected because seizure threshold is lower during early years of brain development. In addition, young children are particularly susceptible to febrile **viral illnesses** (eg, roseola, influenza) associated with **high fever** (≥39.5 C [103 F]), a key risk factor for development of seizures due to **hyperthermia-induced neuronal dysfunction**.

A simple febrile seizure is characterized by a generalized seizure (eg, unresponsiveness, tonic-clonic movements) that is short (<15 min) and does not recur within 24 hours. Benzodiazepines can be used to abort seizures lasting ≥5 mins; however, most self-resolve prior to presentation. Treatment primarily involves **antipyretics** (eg, nonsteroidal anti-inflammatory drugs), which **decrease fever** by inhibiting prostaglandin E_2 synthesis and counteracting the effects of circulating cytokines, resulting in reduction of the thermoregulatory set point in the hypothalamus.

(Choice B) Microbial invasion of the meningeal layers occurs with meningitis, a serious infection that may progress to encephalitis and trigger generalized seizures. However, meningitis causes other findings not seen in this patient, such as nausea/vomiting, photophobia, nuchal rigidity, and prolonged confusion (ie, persisting after post-ictal period).

(Choice C) Neuronal injury from cross-reacting antiviral antibodies describes acute cerebellar ataxia, which often occurs in children following a viral illness but presents with gait instability, impaired coordination, and tremor.

(Choice D) Severe neuronal loss and gliosis in the hippocampus (ie, hippocampal sclerosis) causes mesial temporal lobe epilepsy. Although this condition is associated with a history of childhood febrile seizures, it usually presents in young adults as focal-onset seizures (rather than generalized-onset seizures) characterized by unilateral motor symptoms, a rising epigastric sensation, and auditory/olfactory auras.

(Choice E) Absence seizures are initiated by synchronized slow-wave discharge of thalamocortical tracts. Although these seizures are more common in children with a history of febrile seizures, they are characterized by staring spells of <20 seconds, not unresponsiveness for 40 seconds with shaking movements.

Educational objective:
Febrile seizure is usually a benign neurologic disorder that occurs most commonly in children age 6 months to 5 years who have high fever due to a viral illness. The pathophysiology involves hyperthermia-induced neuronal dysfunction triggering a short (<5 min) generalized seizure; treatment is generally supportive with antipyretics for fever reduction.

not recur within 24 hours. Benzodiazepines can be used to abort seizures lasting ≥5 mins; however, most self-resolve prior to presentation. Treatment primarily involves **antipyretics** (eg, nonsteroidal anti-inflammatory drugs), which **decrease fever** by inhibiting prostaglandin E_2 synthesis and counteracting the effects of circulating cytokines, resulting in reduction of the thermoregulatory set point in the hypothalamus.

(Choice B) Microbial invasion of the meningeal layers occurs with meningitis, a serious infection that may progress to encephalitis and trigger generalized seizures. However, meningitis causes other findings not seen in this patient, such as nausea/vomiting, photophobia, nuchal rigidity, and prolonged confusion (ie, persisting after post-ictal period).

(Choice C) Neuronal injury from cross-reacting antiviral antibodies describes acute cerebellar ataxia, which often occurs in children following a viral illness but presents with gait instability, impaired coordination, and tremor.

(Choice D) Severe neuronal loss and gliosis in the hippocampus (ie, hippocampal sclerosis) causes mesial temporal lobe epilepsy. Although this condition is associated with a history of childhood febrile seizures, it usually presents in young adults as focal-onset seizures (rather than generalized-onset seizures) characterized by unilateral motor symptoms, a rising epigastric sensation, and auditory/olfactory auras.

(Choice E) Absence seizures are initiated by synchronized slow-wave discharge of thalamocortical tracts. Although these seizures are more common in children with a history of febrile seizures, they are characterized by staring spells of <20 seconds, not unresponsiveness for 40 seconds with shaking movements.

Educational objective:
Febrile seizure is usually a benign neurologic disorder that occurs most commonly in children age 6 months to 5 years who have high fever due to a viral illness. The pathophysiology involves hyperthermia-induced neuronal dysfunction triggering a short (<5 min) generalized seizure; treatment is generally supportive with antipyretics for fever reduction.

References

- Febrile seizures.

Pathophysiology	Nervous System	Febrile seizure
Subject	System	Topic

Copyright © UWorld. All rights reserved.

An 8-year-old male with a long history of recurrent pulmonary infections is being evaluated for some neurological symptoms. His gait is unsteady, and he has been known to spontaneously lose his balance and fall. The parents are concerned about their son's language development, as they do not feel that he is progressing appropriately. Additionally, the patient's father states that the child's eyes and head "do not move smoothly" when he is looking at moving objects. Physical examination also reveals numerous superficial blanching nests of distended capillaries on sun-exposed areas of his skin. The genetic defect in this child most likely plays a role in:

A. Mitochondrial iron transport

B. DNA break repair

C. Purine catabolism

D. HLA class II antigen expression

E. Sphingolipid degradation

Submit

An 8-year-old male with a long history of recurrent pulmonary infections is being evaluated for some neurological symptoms. His gait is unsteady, and he has been known to spontaneously lose his balance and fall. The parents are concerned about their son's language development, as they do not feel that he is progressing appropriately. Additionally, the patient's father states that the child's eyes and head "do not move smoothly" when he is looking at moving objects. Physical examination also reveals numerous superficial blanching nests of distended capillaries on sun-exposed areas of his skin. The genetic defect in this child most likely plays a role in:

- A. Mitochondrial iron transport (6%)
- ✓ B. DNA break repair (61%)
- C. Purine catabolism (7%)
- D. HLA class II antigen expression (8%)
- E. Sphingolipid degradation (15%)

Omitted
Correct answer
B

61%
Answered correctly

01 sec
Time Spent

06/11/2020
Last Updated

Explanation

Cerebellar ataxia, telangiectasias, and increased risk of sinopulmonary infections constitute a characteristic triad of ataxia telangiectasia. Telangiectasias are described clinically exactly as they are in the question stem - superficial blanching nests of distended capillaries. Ataxia-telangiectasia also predisposes to an increased risk of hematologic malignancies and causes an immune deficiency consisting of both cell-mediated and humoral dysfunction. The immune deficiency primarily manifests as an IgA deficiency and predisposes to infections of the upper and lower airways.

Explanation

Cerebellar ataxia, telangiectasias, and increased risk of sinopulmonary infections constitute a characteristic triad of ataxia telangiectasia. Telangiectasias are described clinically exactly as they are in the question stem - superficial blanching nests of distended capillaries. Ataxia-telangiectasia also predisposes to an increased risk of hematologic malignancies and causes an immune deficiency consisting of both cell-mediated and humoral dysfunction. The immune deficiency primarily manifests as an IgA deficiency and predisposes to infections of the upper and lower airways.

It is an autosomal recessive condition that occurs due to mutation of ATM gene. ATM (**A**taxia **T**elangiectasia **M**utated) gene is responsible for DNA break repair. DNA in patients with ataxia-telangiectasia is hypersensitive to X-ray radiation that causes multiple chromosomal breaks.

(Choice A) Mitochondrial iron transport is important for heme synthesis. It is inhibited by lead; this is one of the reasons why lead intoxications causes hypochromic anemia.

(Choice C) An example of a disease that results from defective purine catabolism is Lesch-Nyhan syndrome. This is an X-linked recessive disorder that results from a defect in the gene coding for hypoxanthine-guanine phosphoribosyltransferase (HGPRT). This defect leads to a severe hyperuricemia and gout. Of note, these patients classically exhibit self-mutilating behavior in addition to mental retardation, choreoathetoid movements and spasticity.

(Choice D) Bare lymphocyte syndrome is an immunodeficiency resulting from a defect in expression of HLA class II antigens on the surfaces of antigen presenting cells. MHC Class II is needed to present foreign antigen to T cells to elicit a cell mediated AND a humoral response (because T cells must first activate B cells to mature and undergo class switching).

(Choice E) Sphingolipid degradation is defective in Niemann-Pick disease. This disease is caused by an autosomal recessive defect in sphingomyelinase and results in accumulation of sphingomyelin within monocytic cells leading to death in early childhood. Signs and symptoms of disease include hepatosplenomegaly, anemia, motor neuropathy leading to hypotonia and areflexia, and a "cherry red spot" on the macula (not unlike that of Tay-Sachs disease).

Educational objective:
Cerebellar ataxia, telangiectasias, and increased risk of sinopulmonary infections constitute a characteristic triad of ataxia telangiectasia. This illness exhibits autosomal recessive inheritance, and the defect is in a gene that codes for the "ATM" gene which plays a role in DNA break repair. The immune deficiency primarily manifests as an IgA deficiency and predisposes to infections of the upper and lower airways.

It is an autosomal recessive condition that occurs due to mutation of ATM gene. ATM (**A**taxia **T**elangiectasia **M**utated) gene is responsible for DNA break repair. DNA in patients with ataxia-telangiectasia is hypersensitive to X-ray radiation that causes multiple chromosomal breaks.

(Choice A) Mitochondrial iron transport is important for heme synthesis. It is inhibited by lead; this is one of the reasons why lead intoxications causes hypochromic anemia.

(Choice C) An example of a disease that results from defective purine catabolism is Lesch-Nyhan syndrome. This is an X-linked recessive disorder that results from a defect in the gene coding for hypoxanthine-guanine phosphoribosyltransferase (HGPRT). This defect leads to a severe hyperuricemia and gout. Of note, these patients classically exhibit self-mutilating behavior in addition to mental retardation, choreoathetoid movements and spasticity.

(Choice D) Bare lymphocyte syndrome is an immunodeficiency resulting from a defect in expression of HLA class II antigens on the surfaces of antigen presenting cells. MHC Class II is needed to present foreign antigen to T cells to elicit a cell mediated AND a humoral response (because T cells must first activate B cells to mature and undergo class switching).

(Choice E) Sphingolipid degradation is defective in Niemann-Pick disease. This disease is caused by an autosomal recessive defect in sphingomyelinase and results in accumulation of sphingomyelin within monocytic cells leading to death in early childhood. Signs and symptoms of disease include hepatosplenomegaly, anemia, motor neuropathy leading to hypotonia and areflexia, and a "cherry red spot" on the macula (not unlike that of Tay-Sachs disease).

Educational objective:
Cerebellar ataxia, telangiectasias, and increased risk of sinopulmonary infections constitute a characteristic triad of ataxia telangiectasia. This illness exhibits autosomal recessive inheritance, and the defect is in a gene that codes for the "ATM" gene which plays a role in DNA break repair. The immune deficiency primarily manifests as an IgA deficiency and predisposes to infections of the upper and lower airways.

References

- Mechanisms of cerebellar gait ataxia.
- Ataxia-telangiectasia, an evolving phenotype.

Pathophysiology	Nervous System	Ataxia telangiectasia
Subject	System	Topic

1
2
3
4
5
6
7
8
9
10
11
12
13
14
15
16
17
18
19
20
21
22
23
24
25
26
27
28
29

A 14-year-old boy is brought to the clinic by his mother due to changes in vision. For the last few weeks, the patient has been squinting when trying to read the interactive whiteboard in class and has had to sit closer to the front of the room. He has also developed headaches. The patient has no chronic medical conditions and takes no medications. Temperature is 37.2 C (99 F), blood pressure is 116/76 mm Hg, and pulse is 70/min. Examination of the eyes shows equal and reactive pupils. Extraocular muscles are intact, and visual field testing reveals no defects. Visual acuity shows 20/70 in both eyes. His ability to read close text is normal. Which of the following is the most likely cause of this patient's symptoms?

A. Chronically increased intraocular pressure

B. Disturbance in development of the visual cortex

C. Increased anterior-posterior diameter of the eyes

D. Loss of accommodating power of the lens

E. Refracted image focused posterior to the retina

Submit

A 14-year-old boy is brought to the clinic by his mother due to changes in vision. For the last few weeks, the patient has been squinting when trying to read the interactive whiteboard in class and has had to sit closer to the front of the room. He has also developed headaches. The patient has no chronic medical conditions and takes no medications. Temperature is 37.2 C (99 F), blood pressure is 116/76 mm Hg, and pulse is 70/min. Examination of the eyes shows equal and reactive pupils. Extraocular muscles are intact, and visual field testing reveals no defects. Visual acuity shows 20/70 in both eyes. His ability to read close text is normal. Which of the following is the most likely cause of this patient's symptoms?

- A. Chronically increased intraocular pressure (2%)
- B. Disturbance in development of the visual cortex (0%)
- ✓ C. Increased anterior-posterior diameter of the eyes (54%)
- D. Loss of accommodating power of the lens (7%)
- E. Refracted image focused posterior to the retina (35%)

Omitted
Correct answer
C

54%
Answered correctly

01 sec
Time Spent

03/30/2020
Last Updated

Explanation

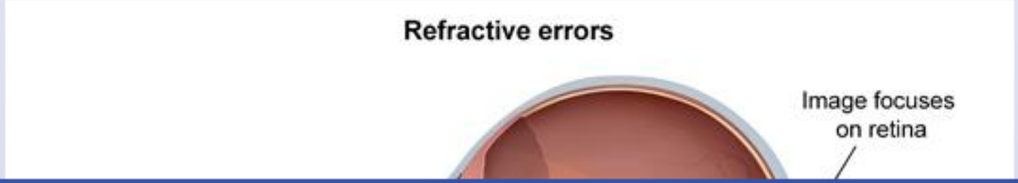

1
2
3
4
5
6
7
8
9
10
11
12
13
14
15
16
17
18
19
20
21
22
23
24
25
26
27
28
29

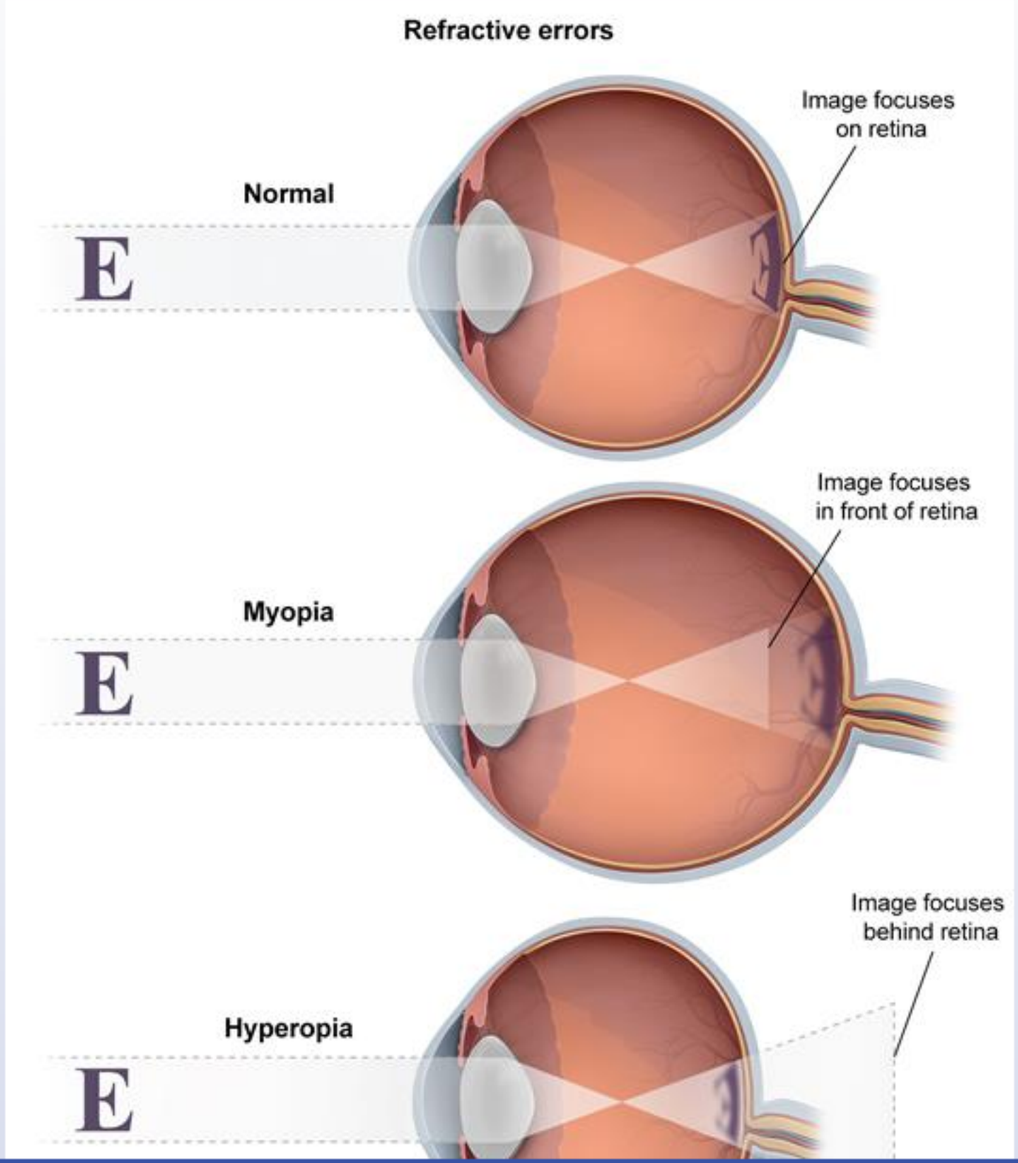

1
2
3
4
5
6
7
8
9
10
11
12
13
14
15
16
17
18
19
20
21
22
23
24
25
26
27
28
29

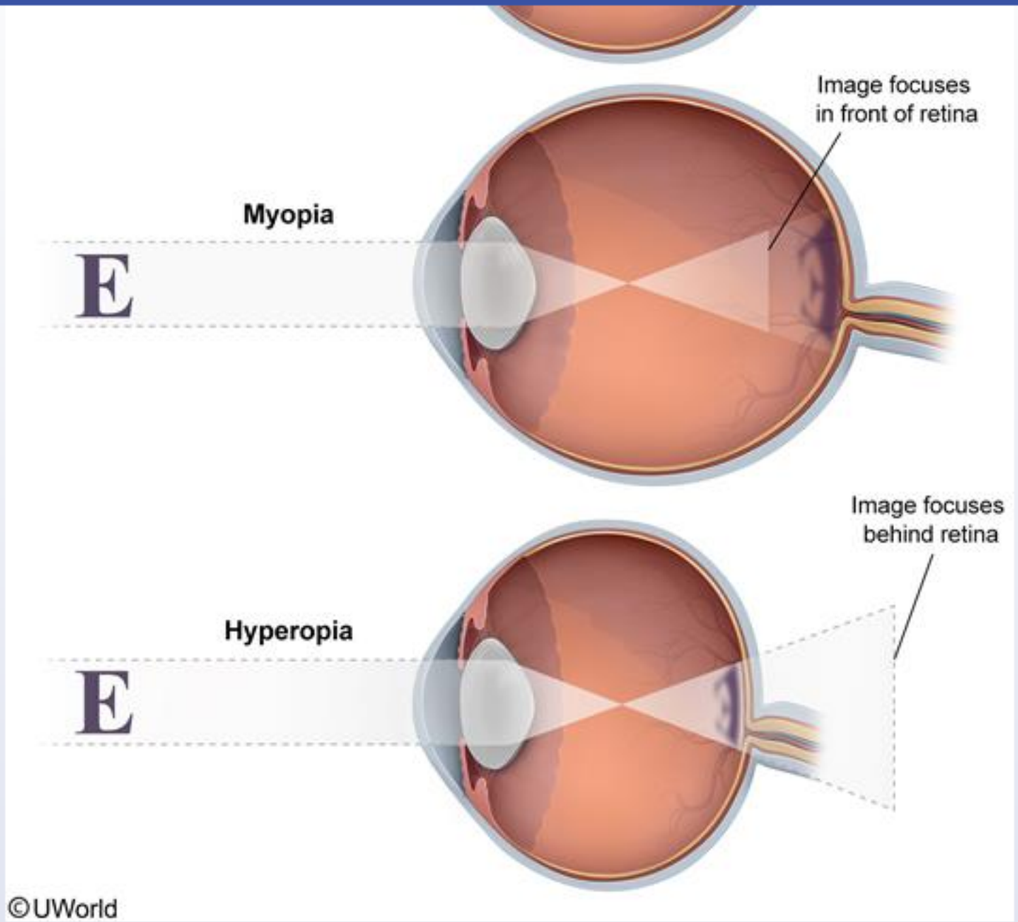

This patient with decreased visual acuity and an otherwise normal ophthalmic examination likely has simple **myopia (nearsightedness)**, a **refractive error** caused by an **increased anterior-posterior diameter** of the eye. The risk is greatest for those with a positive family history or those of East Asian descent.

During the adolescent growth spurt, the axial length of the globe also grows rapidly, making the incidence of new-onset myopia highest in this age group. As the anterior-posterior diameter increases, the focal point of a **refracted image lies anterior to the retina**. For images to be seen clearly, they must be projected directly onto the retina; therefore, the image displacement in myopia causes **blurred vision** of **long-distance**

This patient with decreased visual acuity and an otherwise normal ophthalmic examination likely has simple **myopia (nearsightedness)**, a **refractive error** caused by an **increased anterior-posterior diameter** of the eye. The risk is greatest for those with a positive family history or those of East Asian descent.

During the adolescent growth spurt, the axial length of the globe also grows rapidly, making the incidence of new-onset myopia highest in this age group. As the anterior-posterior diameter increases, the focal point of a **refracted image lies anterior to the retina**. For images to be seen clearly, they must be projected directly onto the retina; therefore, the image displacement in myopia causes **blurred vision** of **long-distance** objects and decreased visual acuity on examination. **Vision** of **nearby** objects is unaffected and appears **clear** in myopic patients. The remainder of the examination, including extraocular movements, peripheral field testing, and funduscopic examination, is normal.

Management is with prescription glasses with a diverging (concave) lens, which refocuses the refracted image onto the retina. The degree of myopia usually stabilizes by early adulthood.

(Choice A) Glaucoma, most commonly due to chronically elevated intraocular pressure, is characterized by optic neuropathy, as evidenced by optic cupping seen on funduscopic examination. Visual acuity may be affected but is a late manifestation after progressive loss of peripheral vision, which is normal in this patient.

(Choice B) Untreated strabismus (misalignment of the eyes) in early childhood can cause unilateral visual cortex suppression to avoid diplopia and eventually lead to amblyopia (decreased visual acuity). This patient's recent symptom onset and normal extraocular movements make this diagnosis unlikely.

(Choice D) Presbyopia is a nonrefractive error that increases with age due to the loss of accommodating power of the lens from decreased elasticity. Blurry vision of nearby objects typically develops in patients age >40.

(Choice E) Hyperopia (farsightedness) is a refractive error characterized by a reduced anterior-posterior diameter of the eye, causing the focal point of the refracted image to be positioned posterior to the retina. In contrast to myopia, hyperopia causes blurred vision of nearby objects and is corrected by a converging (convex) lens.

Educational objective:
Myopia (nearsightedness) is a refractive error in which the focal point of an image falls anterior to the retina due to an increased anterior-posterior diameter of the eyes. Patients have difficulty seeing objects at a distance and have normal near vision.

myopia usually stabilizes by early adulthood.

(Choice A) Glaucoma, most commonly due to chronically elevated intraocular pressure, is characterized by optic neuropathy, as evidenced by optic cupping seen on funduscopic examination. Visual acuity may be affected but is a late manifestation after progressive loss of peripheral vision, which is normal in this patient.

(Choice B) Untreated strabismus (misalignment of the eyes) in early childhood can cause unilateral visual cortex suppression to avoid diplopia and eventually lead to amblyopia (decreased visual acuity). This patient's recent symptom onset and normal extraocular movements make this diagnosis unlikely.

(Choice D) Presbyopia is a nonrefractive error that increases with age due to the loss of accommodating power of the lens from decreased elasticity. Blurry vision of nearby objects typically develops in patients age >40.

(Choice E) Hyperopia (farsightedness) is a refractive error characterized by a reduced anterior-posterior diameter of the eye, causing the focal point of the refracted image to be positioned posterior to the retina. In contrast to myopia, hyperopia causes blurred vision of nearby objects and is corrected by a converging (convex) lens.

Educational objective:
Myopia (nearsightedness) is a refractive error in which the focal point of an image falls anterior to the retina due to an increased anterior-posterior diameter of the eyes. Patients have difficulty seeing objects at a distance and have normal near vision.

References

- Childhood myopia: epidemiology, risk factors, and prevention.
- Prevention of progression in myopia: a systematic review.
- The science behind myopia

Pathophysiology	Ophthalmology	Refractive errors
Subject	System	Topic

Copyright © UWorld. All rights reserved.

During the adolescent growth spurt, the axial length of the globe also grows rapidly, making the incidence of new-onset myopia highest in this age.

Exhibit Display

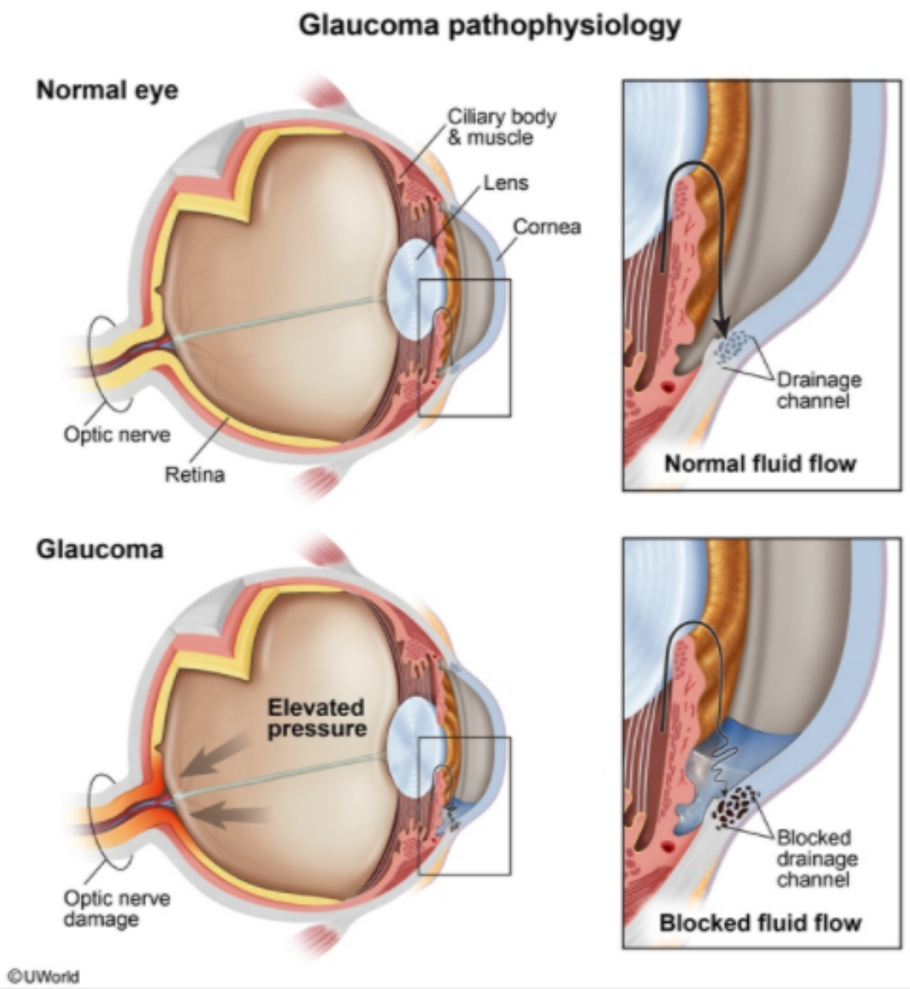

Zoom In Zoom Out Reset Add To Flash Card

- Prevention of progression in myopia: a systematic review.

During the adolescent growth spurt, the axial length of the globe also grows rapidly, making the incidence of new-onset myopia highest in this age.

Exhibit Display

Strabismus

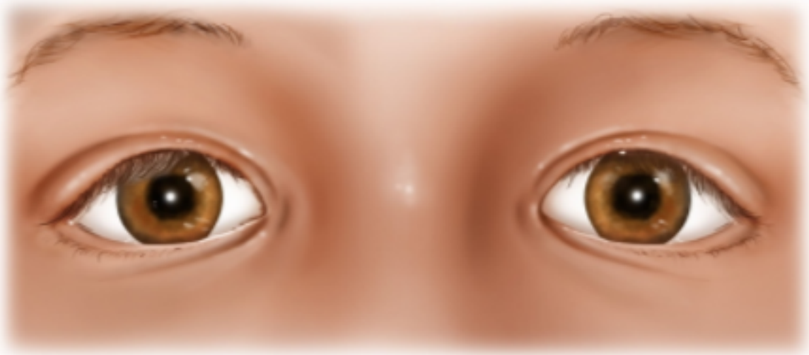

Normal eyes

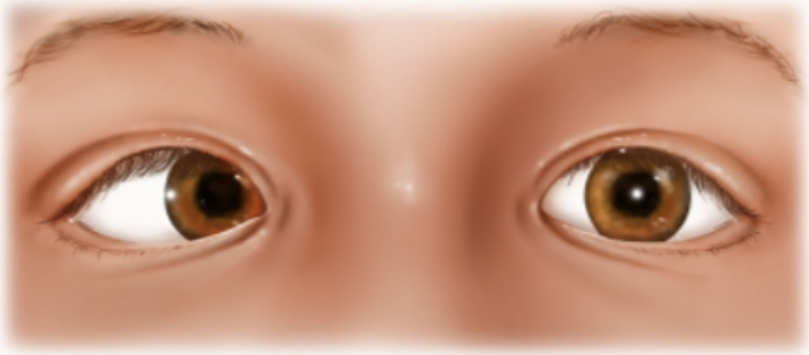

Esotropia (strabismus)

©UWorld

Zoom In Zoom Out Reset Add To Flash Card

- Prevention of progression in myopia: a systematic review.

During the adolescent growth spurt, the axial length of the globe also grows rapidly, making the incidence of new-onset myopia highest in this age.

Exhibit Display

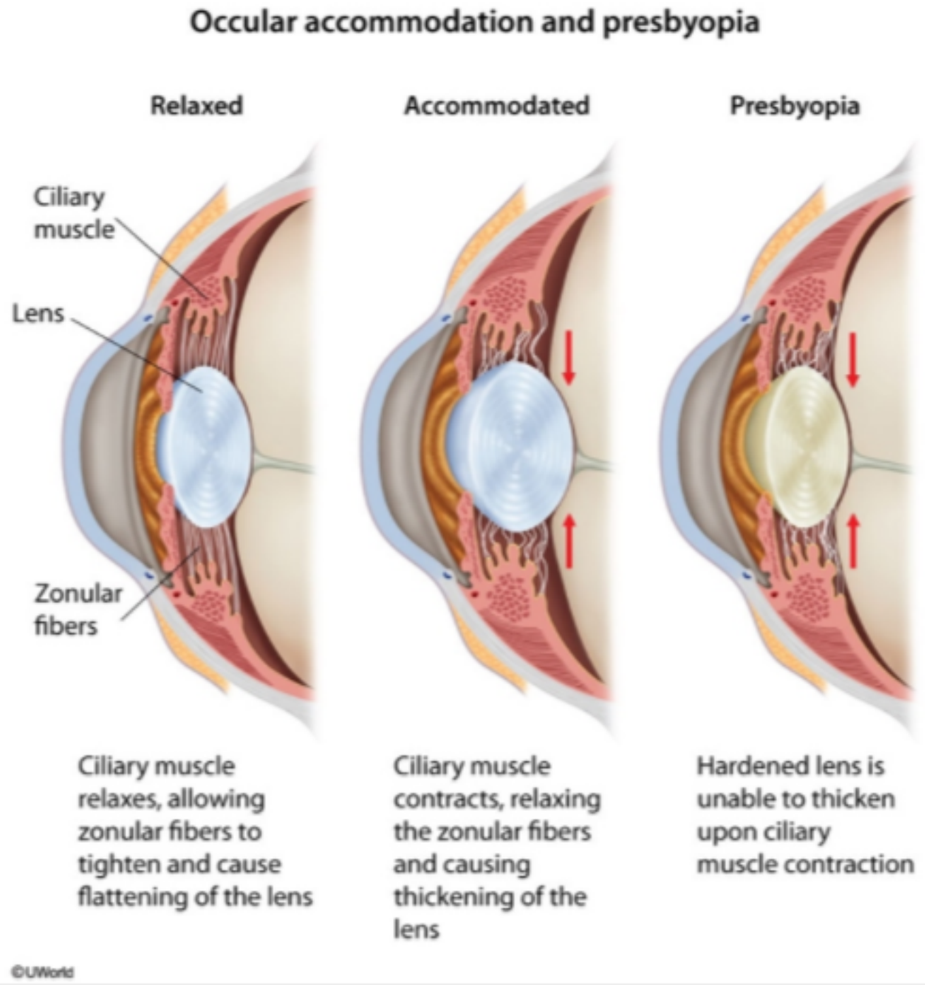

Zoom In Zoom Out Reset Add To Flash Card

- Prevention of progression in myopia: a systematic review.

group. As the anterior-posterior diameter increases, the focal point of a **refracted image lies anterior to the retina**. For images to be seen

Exhibit Display

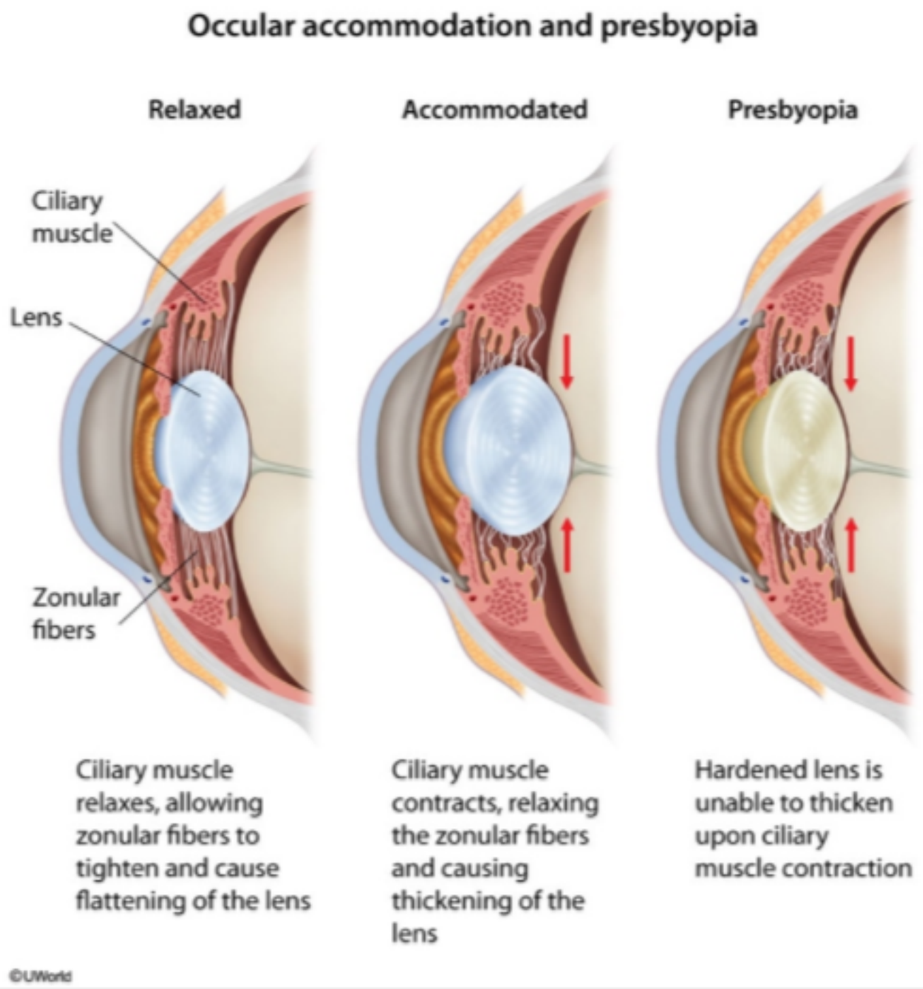

Zoom In Zoom Out Reset Add To Flash Card

The science behind myopia

group. As the anterior-posterior diameter increases, the focal point of a **refracted image lies anterior to the retina**. For images to be seen

Exhibit Display

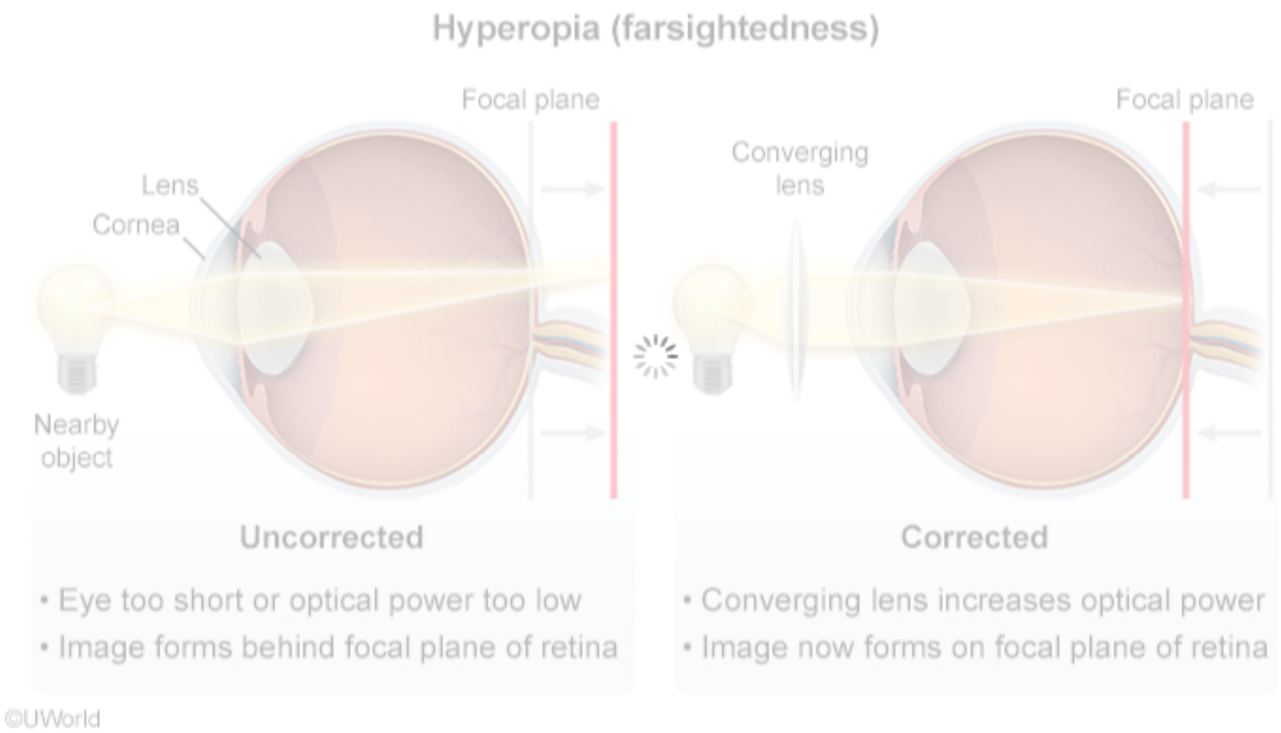

Zoom In Zoom Out Reset Add To Flash Card

• The science behind myopia

1
2
3
4
5
6
7
8
9
10
11
12
13
14
15
16
17
18
19
20
21
22
23
24
25
26
27
28
29

A 38-year-old woman is being evaluated for intermittent tingling and numbness of the left hand for the past several months. Her symptoms predominantly involve the fourth and fifth digits and are often brought on by driving a car. Physical examination shows no abnormalities. An electrodiagnostic study is performed, during which a nerve stimulator is placed on the left fifth digit and a surface recorder is placed over the ulnar nerve above the elbow. Electrical stimulus is applied, and the graph obtained is shown below. Results from the asymptomatic contralateral extremity are also shown. Which of the following is primarily affected in this patient?

A. Neuronal axons

B. Neuronal cell bodies

C. Postsynaptic membrane

D. Schwann cells

E. Synaptic vesicles

Submit

A 38-year-old woman is being evaluated for intermittent tingling and numbness of the left hand for the past several months. Her symptoms predominantly involve the fourth and fifth digits and are often brought on by driving a car. Physical examination shows no abnormalities. An electrodiagnostic study is performed, during which a nerve stimulator is placed on the left fifth digit and a surface recorder is placed over the ulnar nerve above the elbow. Electrical stimulus is applied, and the graph obtained is shown below. Results from the asymptomatic contralateral extremity are also shown. Which of the following is primarily affected in this patient?

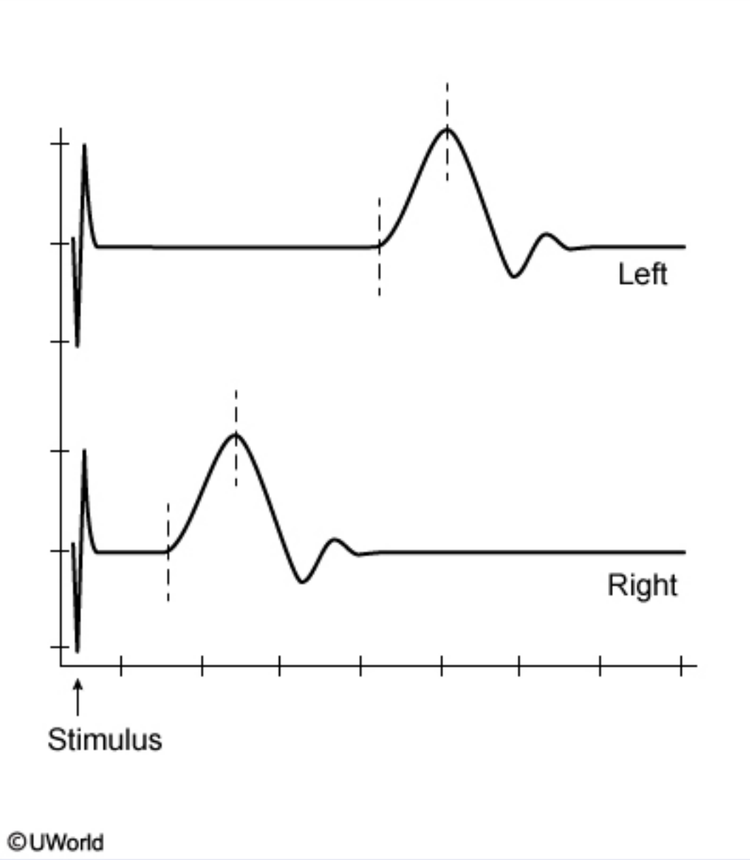

A. Neuronal axons

1
2
3
4
5
6
7
8
9
10
11
12
13
14
15
16
17
18
19
20
21
22
23
24
25
26
27
28
29

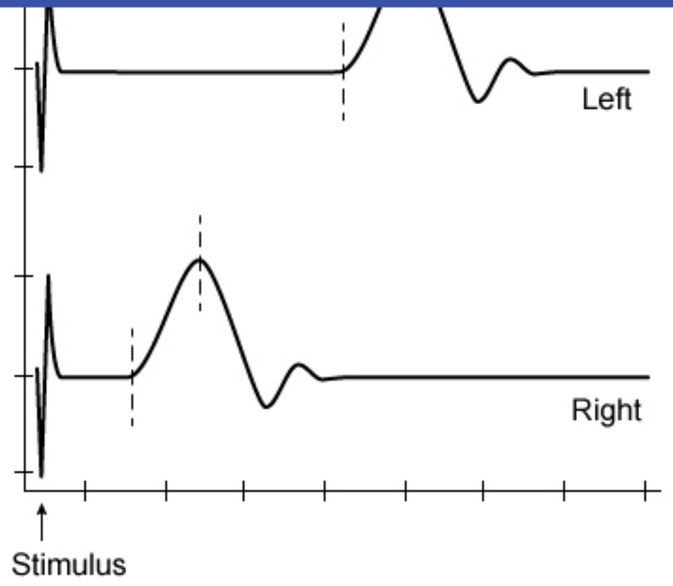

©UWorld

A. Neuronal axons

B. Neuronal cell bodies

C. Postsynaptic membrane

D. Schwann cells

E. Synaptic vesicles

Submit

1
2
3
4
5
6
7
8
9
10
11
12
13
14
15
16
17
18
19
20
21
22
23
24
25
26
27
28
29

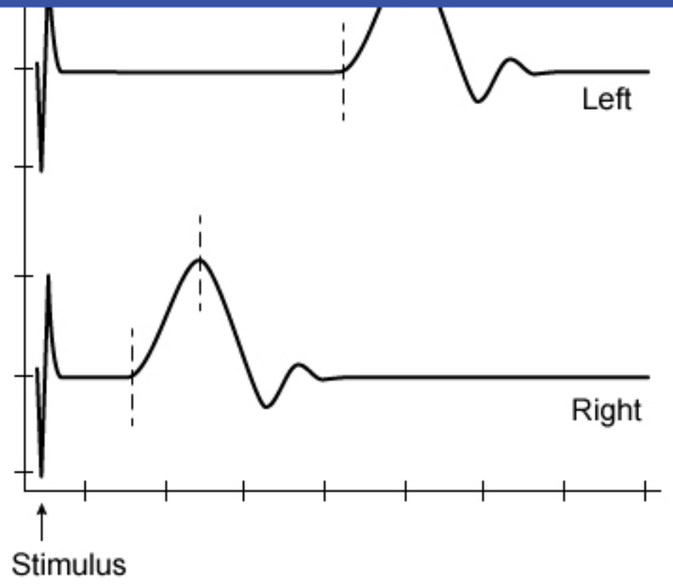

©UWorld

A. Neuronal axons (23%)

B. Neuronal cell bodies (2%)

C. Postsynaptic membrane (3%)

✓ D. Schwann cells (68%)

E. Synaptic vesicles (1%)

Omitted
Correct answer

68%
Answered correctly

05 secs
Time Spent

03/26/2020
Last Updated

1
2
3
4
5
6
7
8
9
10
11
12
13
14
15
16
17
18
19
20
21
22
23
24
25
26
27
28
29

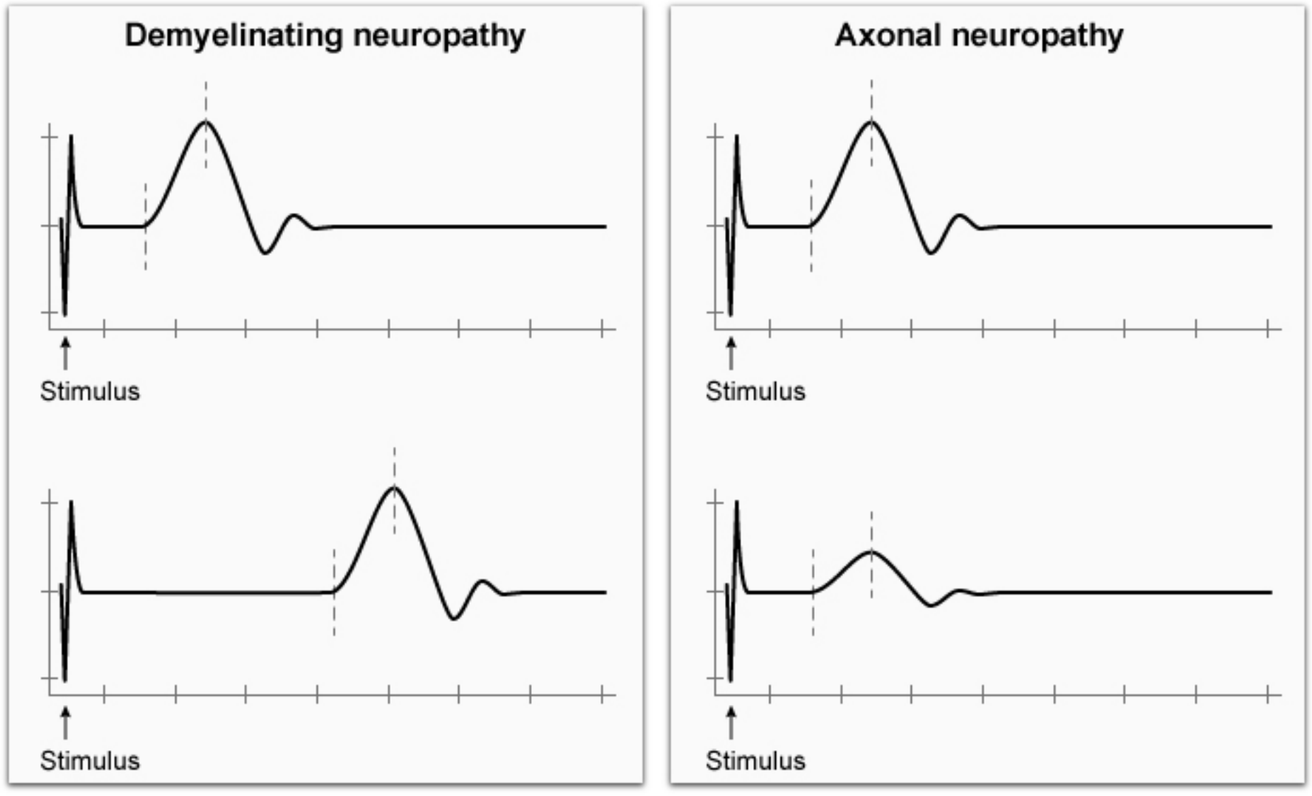

©UWorld

A **nerve conduction study** (NCS) measures the amplitude, velocity, and latency of an electrical stimulus applied to an isolated nerve and can help differentiate between demyelinating and axonal neuropathies:

- **Demyelinating neuropathies** are caused by damage to the myelin sheath. Loss of insulation results in **delayed** (or blocked) **nerve conduction velocity**.
- **Axonal neuropathies** are caused by damage to the nerve axon. Loss of axon fibers results in **reduced signal amplitude**.

A **nerve conduction study** (NCS) measures the amplitude, velocity, and latency of an electrical stimulus applied to an isolated nerve and can help differentiate between demyelinating and axonal neuropathies:

- **Demyelinating neuropathies** are caused by damage to the myelin sheath. Loss of insulation results in **delayed** (or blocked) **nerve conduction velocity**.
- **Axonal neuropathies** are caused by damage to the nerve axon. Loss of axon fibers results in **reduced signal amplitude**.

This patient has a delay in left-sided ulnar conduction velocity, indicating a **demyelinating ulnar mononeuropathy**. Focal nerve **compression** (eg, compression of the ulnar nerve at the elbow) is the most common cause of mononeuropathy and results in nerve ischemia, leading to apoptosis of Schwann cells and **localized demyelination**. In addition to sensory symptoms, patients with ulnar neuropathy may also have weakness of the fourth and fifth digits, elbow pain, and worsening of symptoms with elbow or wrist flexion. Severe disease can lead to wasting of the hand muscles and an ulnar claw deformity.

(Choice A) An axonal neuropathy would primarily show diminished amplitude, rather than reduced velocity of nerve conduction. Common causes of axonal neuropathy include diabetes mellitus, toxins (eg, chemotherapeutic drugs), hypothyroidism, vitamin B_{12} deficiency, and vasculitis.

(Choice B) Neuronal cell bodies are located in the dorsal root ganglia and the anterior horn of the spinal cord. Neuronal cell body damage could potentially result in reduced signal amplitude if there is secondary axonal degeneration.

(Choice C) Myasthenia gravis is due to autoimmune attack on the acetylcholine receptors of the postsynaptic membrane. This causes fatigable weakness of the ocular, facial, and proximal muscles. NCS is typically normal, but muscle stimulation studies demonstrate a reduction in *motor signal strength* with repetitive stimuli.

(Choice E) Botulinum toxin blocks acetylcholine release from presynaptic membranes of the neuromuscular junction by impairing fusion of secretory vesicles with the synaptic membrane. Patients typically develop cranial neuropathies with symmetric, descending flaccid paralysis. NCS is typically normal; muscle stimulation studies may show a reduction in *motor signal strength* that improves with repetitive stimuli.

Educational objective:
Ulnar neuropathy is characterized by numbness of the fourth and fifth digits, pain, and weakness. It is most commonly caused by compressive injury, leading to tissue ischemia and demyelination (Schwann cell injury). A nerve conduction study can help differentiate demyelinating versus axonal neuropathies; demyelination causes slowed or blocked nerve conduction velocity whereas axonal injury leads to a reduction in signal

- **Demyelinating neuropathies** are caused by damage to the myelin sheath. Loss of insulation results in **delayed** (or blocked) **nerve conduction velocity**.
- **Axonal neuropathies** are caused by damage to the nerve axon. Loss of axon fibers results in **reduced signal amplitude**.

This patient has a delay in left-sided ulnar conduction velocity, indicating a **demyelinating ulnar mononeuropathy**. Focal nerve **compression** (eg, compression of the ulnar nerve at the elbow) is the most common cause of mononeuropathy and results in nerve ischemia, leading to apoptosis of Schwann cells and **localized demyelination**. In addition to sensory symptoms, patients with ulnar neuropathy may also have weakness of the fourth and fifth digits, elbow pain, and worsening of symptoms with elbow or wrist flexion. Severe disease can lead to wasting of the hand muscles and an ulnar claw deformity.

(Choice A) An axonal neuropathy would primarily show diminished amplitude, rather than reduced velocity of nerve conduction. Common causes of axonal neuropathy include diabetes mellitus, toxins (eg, chemotherapeutic drugs), hypothyroidism, vitamin B_{12} deficiency, and vasculitis.

(Choice B) Neuronal cell bodies are located in the dorsal root ganglia and the anterior horn of the spinal cord. Neuronal cell body damage could potentially result in reduced signal amplitude if there is secondary axonal degeneration.

(Choice C) Myasthenia gravis is due to autoimmune attack on the acetylcholine receptors of the postsynaptic membrane. This causes fatigable weakness of the ocular, facial, and proximal muscles. NCS is typically normal, but muscle stimulation studies demonstrate a reduction in *motor signal strength* with repetitive stimuli.

(Choice E) Botulinum toxin blocks acetylcholine release from presynaptic membranes of the neuromuscular junction by impairing fusion of secretory vesicles with the synaptic membrane. Patients typically develop cranial neuropathies with symmetric, descending flaccid paralysis. NCS is typically normal; muscle stimulation studies may show a reduction in *motor signal strength* that improves with repetitive stimuli.

Educational objective:
Ulnar neuropathy is characterized by numbness of the fourth and fifth digits, pain, and weakness. It is most commonly caused by compressive injury, leading to tissue ischemia and demyelination (Schwann cell injury). A nerve conduction study can help differentiate demyelinating versus axonal neuropathies; demyelination causes slowed or blocked nerve conduction velocity whereas axonal injury leads to a reduction in signal strength.

Pathophysiology Nervous System Peripheral neuropathy

1
2
3
4
5
6
7
8
9
10
11
12
13
14
15
16
17
18
19
20
21
22
23
24
25
26
27
28
29

Exhibit Display

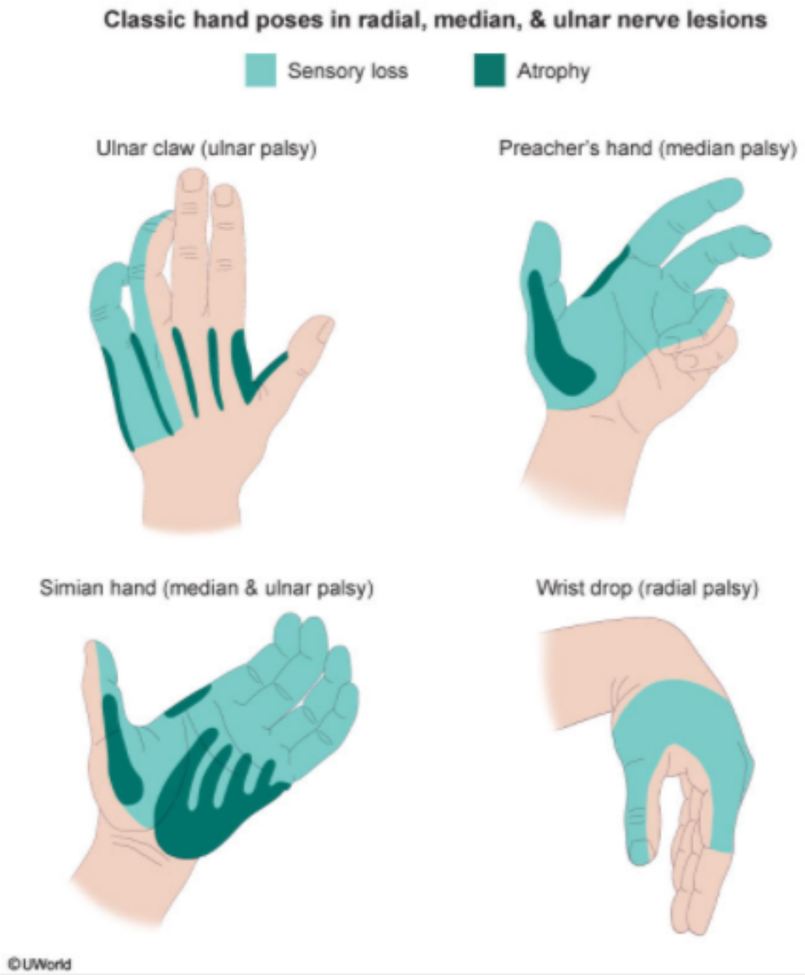

Zoom In | Zoom Out | Reset | Add To New Card | Existing Card

secretory vesicles with the synaptic membrane. Patients typically develop cranial neuropathies with symmetric, descending flaccid paralysis.

This patient has a delay in left-sided ulnar conduction velocity, indicating a **demyelinating ulnar mononeuropathy**. Focal nerve **compression** (eg, compression of the ulnar nerve at the elbow) is the most common cause of mononeuropathy and results in nerve ischemia, leading to apoptosis of Schwann cells and **localized demyelination**. In addition to sensory symptoms, patients with ulnar neuropathy may also have weakness of the fourth and fifth digits, elbow pain, and worsening of symptoms with elbow or wrist flexion. Severe disease can lead to wasting of the hand muscles and an ulnar claw deformity.

(Choice A) An axonal neuropathy would primarily show diminished amplitude, rather than reduced velocity of nerve conduction. Common causes of axonal neuropathy include diabetes mellitus, toxins (eg, chemotherapeutic drugs), hypothyroidism, vitamin B_{12} deficiency, and vasculitis.

(Choice B) Neuronal cell bodies are located in the dorsal root ganglia and the anterior horn of the spinal cord. Neuronal cell body damage could potentially result in reduced signal amplitude if there is secondary axonal degeneration.

(Choice C) Myasthenia gravis is due to autoimmune attack on the acetylcholine receptors of the postsynaptic membrane. This causes fatigable weakness of the ocular, facial, and proximal muscles. NCS is typically normal, but muscle stimulation studies demonstrate a reduction in *motor signal strength* with repetitive stimuli.

(Choice E) Botulinum toxin blocks acetylcholine release from presynaptic membranes of the neuromuscular junction by impairing fusion of secretory vesicles with the synaptic membrane. Patients typically develop cranial neuropathies with symmetric, descending flaccid paralysis. NCS is typically normal; muscle stimulation studies may show a reduction in *motor signal strength* that improves with repetitive stimuli.

Educational objective:
Ulnar neuropathy is characterized by numbness of the fourth and fifth digits, pain, and weakness. It is most commonly caused by compressive injury, leading to tissue ischemia and demyelination (Schwann cell injury). A nerve conduction study can help differentiate demyelinating versus axonal neuropathies; demyelination causes slowed or blocked nerve conduction velocity whereas axonal injury leads to a reduction in signal strength.

Pathophysiology	Nervous System	Peripheral neuropathy
Subject	System	Topic

Copyright © UWorld. All rights reserved.

1
2
3
4
5
6
7
8
9
10
11
12
13
14
15
16
17
18
19
20
21
22
23
24
25
26
27
28
29

A 17-year-old boy is brought to the clinic due to poor vision at night. The patient developed mild difficulty seeing at night about 4 months ago, and it has slowly worsened. Visual field examination shows visual loss in the midperiphery. External eye examination reveals normal tear formation. Funduscopic examination shows bilateral optic disc pallor, attenuation of retinal vessels, and areas of dark discoloration in the retina. Which of the following is the most likely mechanism of this patient's visual impairment?

A. Biallelic inactivation of *RB1* gene

B. Genetic progressive retinal dystrophy

C. Increased intracranial pressure

D. Poor aqueous outflow due to narrow angle

E. Retinal artery occlusion

Submit

A 17-year-old boy is brought to the clinic due to poor vision at night. The patient developed mild difficulty seeing at night about 4 months ago, and it has slowly worsened. Visual field examination shows visual loss in the midperiphery. External eye examination reveals normal tear formation. Funduscopic examination shows bilateral optic disc pallor, attenuation of retinal vessels, and areas of dark discoloration in the retina. Which of the following is the most likely mechanism of this patient's visual impairment?

A. Biallelic inactivation of *RB1* gene (16%)
✓ B. Genetic progressive retinal dystrophy (59%)
C. Increased intracranial pressure (8%)
D. Poor aqueous outflow due to narrow angle (4%)
E. Retinal artery occlusion (10%)

Omitted
Correct answer
B

59%
Answered correctly

02 secs
Time Spent

05/15/2020
Last Updated

Explanation

Retinitis pigmentosa	
Etiology	• Genetic dystrophy • Progressive retinal degeneration (photoreceptors, pigmented epithelium)
	• Loss of rods: ◦ Night blindness

Retinitis pigmentosa	
Etiology	• Genetic dystrophy • Progressive retinal degeneration (photoreceptors, pigmented epithelium)

Clinical features	• Loss of rods:
	  ◦ Night blindness
	  ◦ Peripheral visual field loss
	• Loss of cones:
	  ◦ Decreased central visual acuity (late finding)

Funduscopic changes	• Retinal vessel attenuation (likely due to altered metabolic demand) • Optic disc pallor (optic nerve atrophy and gliosis) • Pigment accumulation (characteristic bone-spicule pattern around vessels)

This patient has poor night vision, visual field loss, and funduscopic changes (eg, pigment accumulation, optic disc pallor, retinal vessel attenuation) consistent with **retinitis pigmentosa**, a genetic disease characterized by **progressive dystrophy** of the retinal pigmented epithelium and **photoreceptors** (eg, rods, cones).

Rods, which are highly metabolically active and most prevalent in the periphery, are affected first, leading to the initial manifestations of **progressive night blindness** and **loss of peripheral vision**. Early funduscopic changes include retinal vessel attenuation (ie, narrow vessels likely due to alterations in retinal metabolic demand) and a waxy, pale optic disc (due to optic nerve atrophy and gliosis).

In advanced disease, loss of cones (most prevalent in the central retina) causes decreased central visual acuity. Degeneration of retinal pigmented epithelial cells releases **pigment**, which **deposits** in a characteristic **bone-spicule pattern** over the course of the disease.

(Choice A) Retinoblastoma, which is caused by inactivation of both alleles of the *RB1* gene (ie, 2-hit hypothesis), typically presents in the first 3 years of life with leukocoria (ie, white pupillary reflex), strabismus, and a creamy-white mass on funduscopic examination.

(Choice C) Increased intracranial pressure can be associated with transient visual obscuration and decreased visual acuity. However, other symptoms (eg, headache, vomiting) are also typically present and papilledema with blurred optic disc margins would be seen on funduscopy.

1
2
3
4
5
6
7
8
9
10
11
12
13
14
15
16
17
18
19
20
21
22
23
24
25
26
27
28
29

Funduscopic changes	• Optic disc pallor (optic nerve atrophy and gliosis) • Pigment accumulation (characteristic bone-spicule pattern around vessels)

This patient has poor night vision, visual field loss, and funduscopic changes (eg, pigment accumulation, optic disc pallor, retinal vessel attenuation) consistent with **retinitis pigmentosa**, a genetic disease characterized by **progressive dystrophy** of the retinal pigmented epithelium and **photoreceptors** (eg, rods, cones).

Rods, which are highly metabolically active and most prevalent in the periphery, are affected first, leading to the initial manifestations of **progressive night blindness** and **loss of peripheral vision**. Early funduscopic changes include retinal vessel attenuation (ie, narrow vessels likely due to alterations in retinal metabolic demand) and a waxy, pale optic disc (due to optic nerve atrophy and gliosis).

In advanced disease, loss of cones (most prevalent in the central retina) causes decreased central visual acuity. Degeneration of retinal pigmented epithelial cells releases **pigment**, which **deposits** in a characteristic **bone-spicule pattern** over the course of the disease.

(Choice A) Retinoblastoma, which is caused by inactivation of both alleles of the *RB1* gene (ie, 2-hit hypothesis), typically presents in the first 3 years of life with leukocoria (ie, white pupillary reflex), strabismus, and a creamy-white mass on funduscopic examination.

(Choice C) Increased intracranial pressure can be associated with transient visual obscuration and decreased visual acuity. However, other symptoms (eg, headache, vomiting) are also typically present and papilledema with blurred optic disc margins would be seen on funduscopy.

(Choice D) Angle-closure glaucoma occurs due to narrowing of the angle between the iris and the cornea, which blocks aqueous outflow. Patients typically have acute eye pain and vision loss with conjunctival erythema, cornea edema, and a mid-dilated, poorly reactive pupil. Optic nerve atrophy secondary to chronically increased intraocular pressure results in optic nerve cupping on funduscopy.

(Choice E) Central retinal artery occlusion typically presents with unilateral painless acute vision loss in patients age >40 with thromboembolic risk factors (eg, hypertension). Retinal whitening and a cherry-red macula are the characteristic funduscopic changes.

Educational objective:
Retinitis pigmentosa is a genetic condition resulting in progressive dystrophy of retinal pigmented epithelium and photoreceptors. Patients typically present with progressive night blindness and loss of peripheral vision due to early loss of rods, which are highly metabolically active. Funduscopic examination may show dark pigments deposited in a bone-spicule pattern in addition to retinal vessel attenuation and optic disc pallor.

1
2
3
4
5
6
7
8
9
10
11
12
13
14
15
16
17
18
19
20
21
22
23
24
25
26
27
28
29

This patient has poor night vision, visual field loss, and fundoscopic changes (eg, pigment accumulation, optic disc pallor, retinal vessel

Exhibit Display

Retinitis pigmentosa

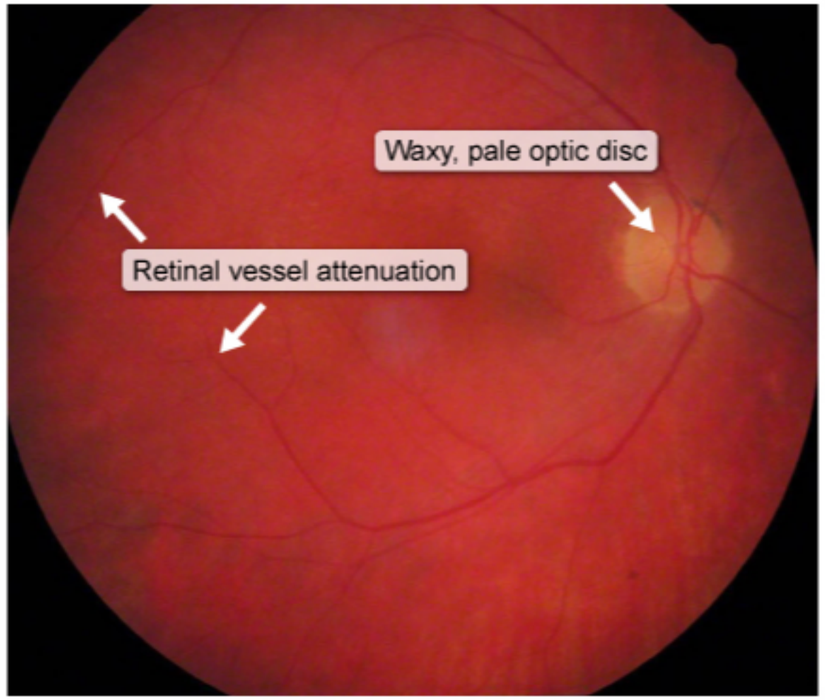

©UWorld

Zoom In
Zoom Out
Reset
Add To Flash Card

- Retinitis pigmentosa.

1
2
3
4
5
6
7
8
9
10
11
12
13
14
15
16
17
18
19
20
21
22
23
24
25
26
27
28
29

Exhibit Display

Knudson's 2-hit hypothesis

Both copies of the gene must be knocked out to promote malignancy.

Sporadic cancer:
2 acquired mutations

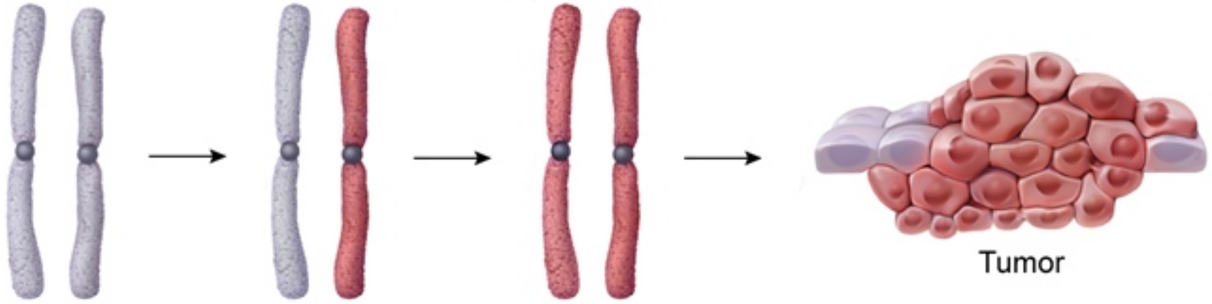

Hereditary cancer:
1 inherited and 1 acuired mutation

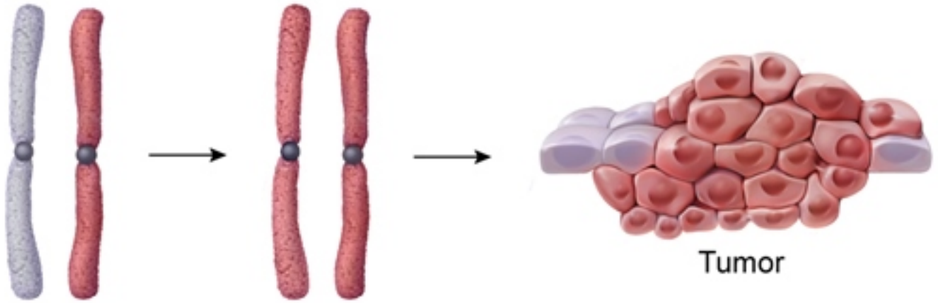

Zoom In Zoom Out Reset Add To Flash Card

- Retinitis pigmentosa.

1
2
3
4
5
6
7
8
9
10
11
12
13
14
15
16
17
18
19
20
21
22
23
24
25
26
27
28
29

This patient has poor night vision, visual field loss, and funduscopic changes (eg, pigment accumulation, optic disc pallor, retinal vessel

Exhibit Display

Normal eyes & white reflex

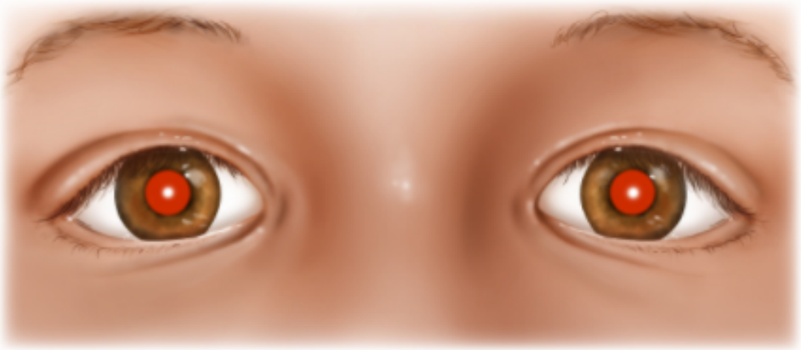

Normal eyes
Red reflexes & corneal light reflexes are equal.

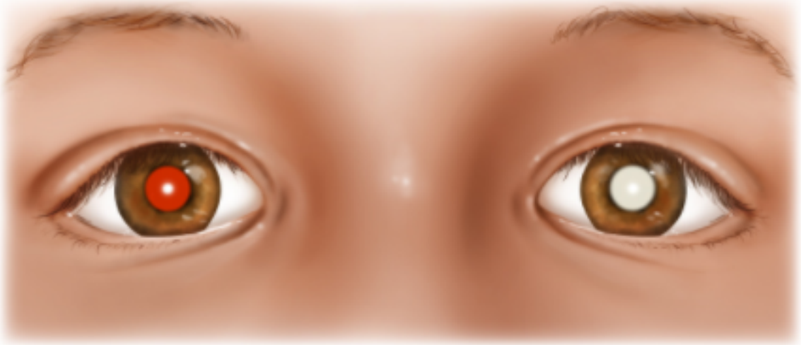

Absent reflex
White reflex on abnormal eye can result from opacities of the lens (eg, cataract) or tumor (eg, retinoblastoma).

©UWorld

Zoom In
Zoom Out
Reset
Add To Flash Card

- Retinitis pigmentosa.

1
2
3
4
5
6
7
8
9
10
11
12
13
14
15
16
17
18
19
20
21
22
23
24
25
26
27
28
29

This patient has poor night vision, visual field loss, and fundoscopic changes (eg, pigment accumulation, optic disc pallor, retinal vessel

Exhibit Display

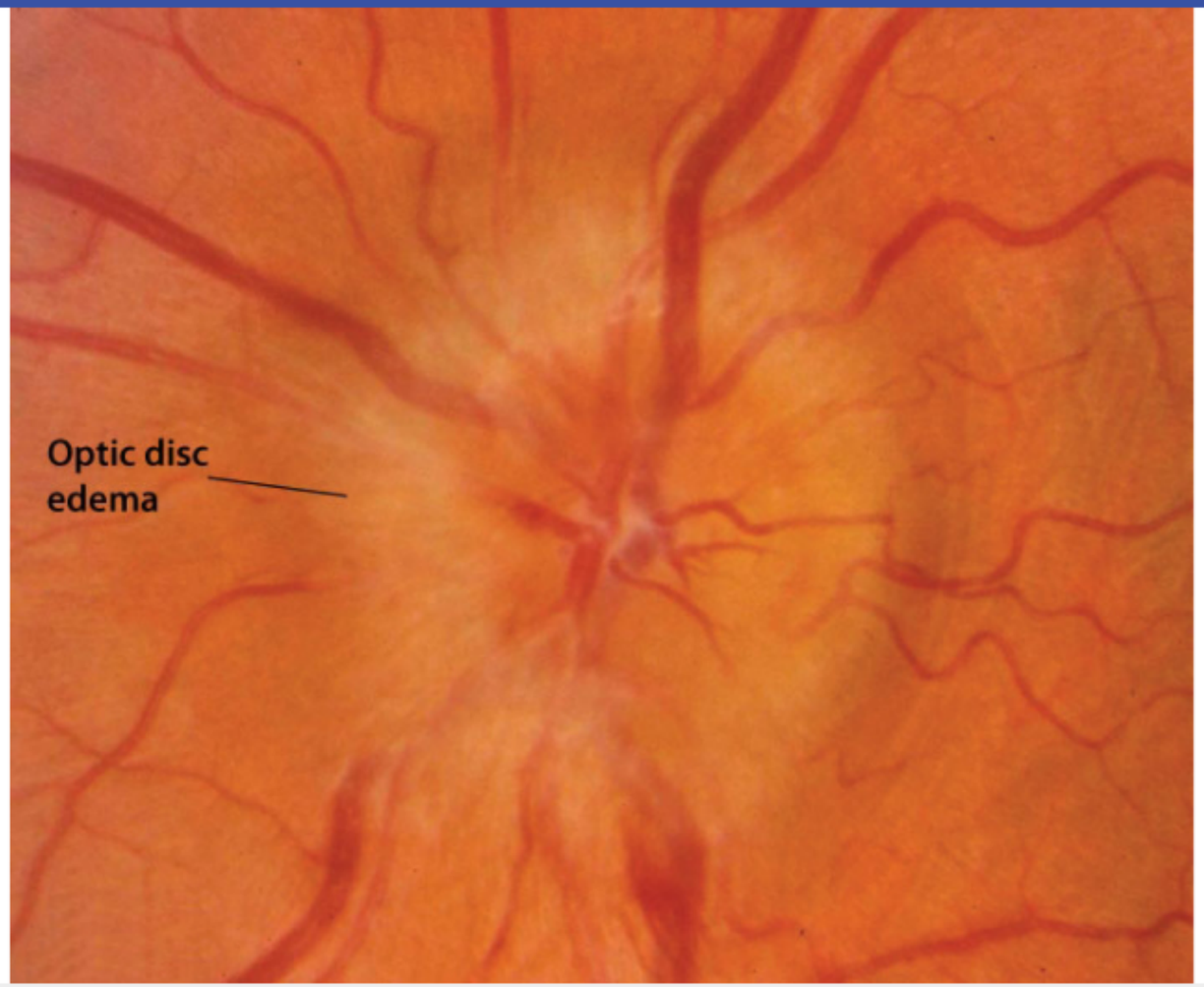

Zoom In
Zoom Out
Reset
Add To Flash Card

- Retinitis pigmentosa.

1
2
3
4
5
6
7
8
9
10
11
12
13
14
15
16
17
18
19
20
21
22
23
24
25
26
27
28
29

This patient has poor night vision, visual field loss, and funduscopic changes (eg, pigment accumulation, optic disc pallor, retinal vessel

Exhibit Display

Angle-closure glaucoma

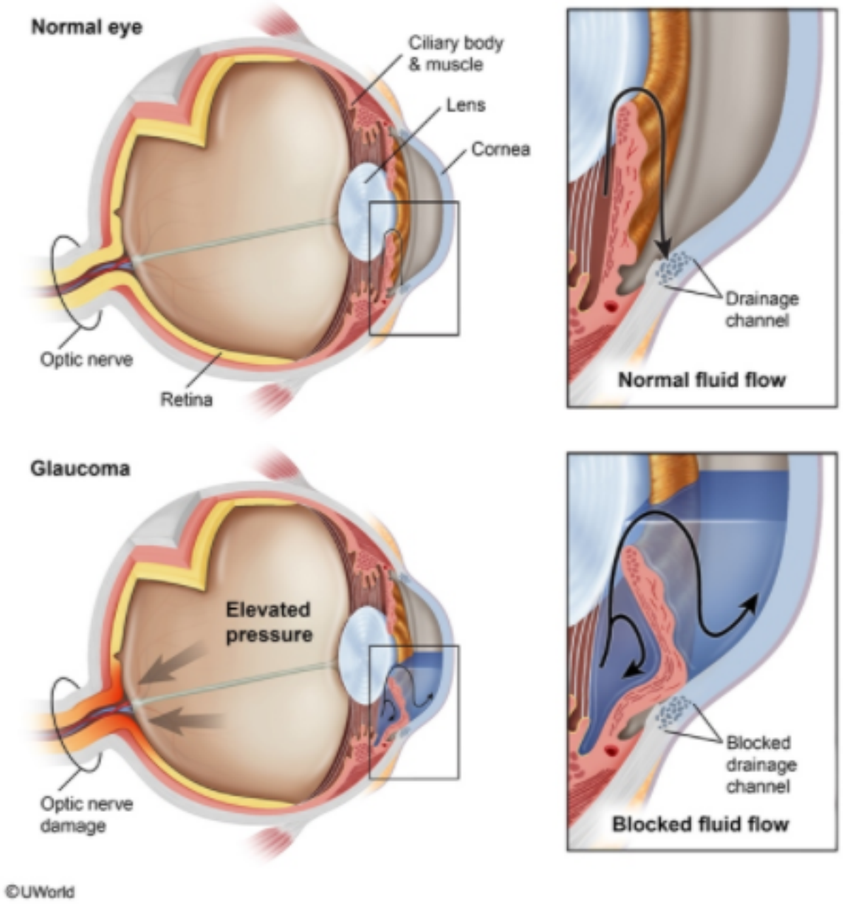

Zoom In Zoom Out Reset Add To Flash Card

- Retinitis pigmentosa.

1
2
3
4
5
6
7
8
9
10
11
12
13
14
15
16
17
18
19
20
21
22
23
24
25
26
27
28
29

This patient has poor night vision, visual field loss, and funduscopic changes (eg, pigment accumulation, optic disc pallor, retinal vessel

Exhibit Display

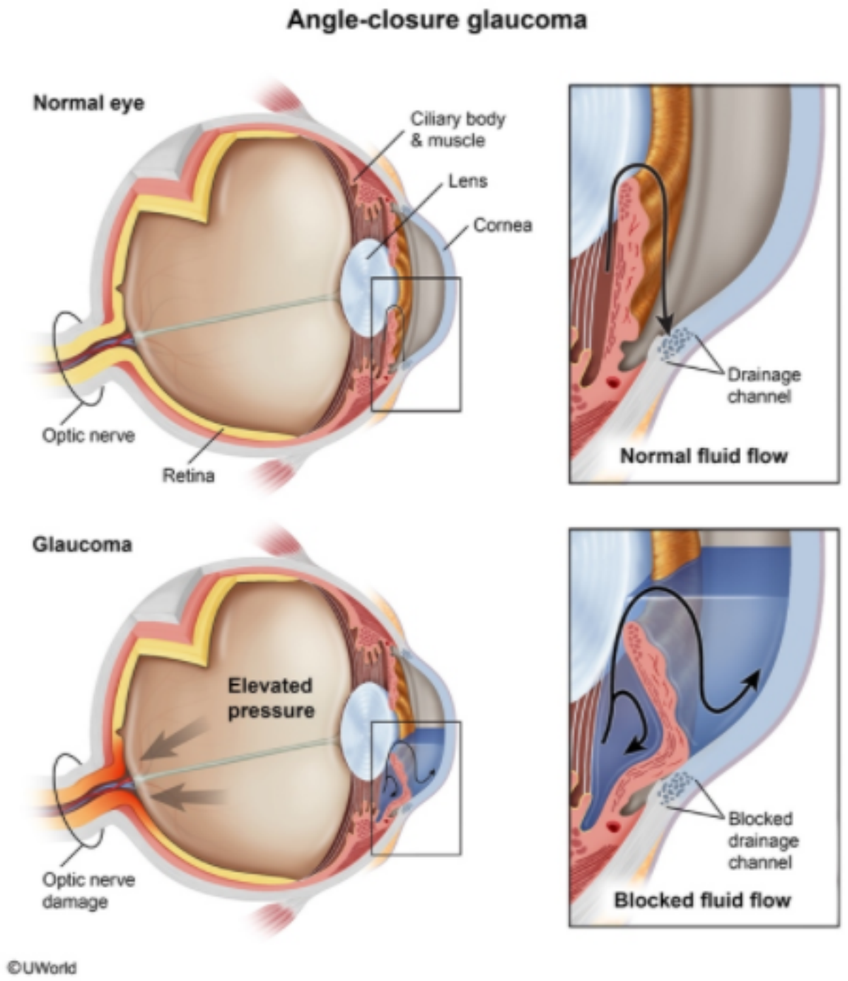

Zoom In Zoom Out Reset Add To Flash Card

- Retinitis pigmentosa.

1
2
3
4
5
6
7
8
9
10
11
12
13
14
15
16
17
18
19
20
21
22
23
24
25
26
27
28
29

This patient has poor night vision, visual field loss, and funduscopic changes (eg, pigment accumulation, optic disc pallor, retinal vessel

Exhibit Display

Optic disc in glaucoma

Normal	Open-angle glaucoma
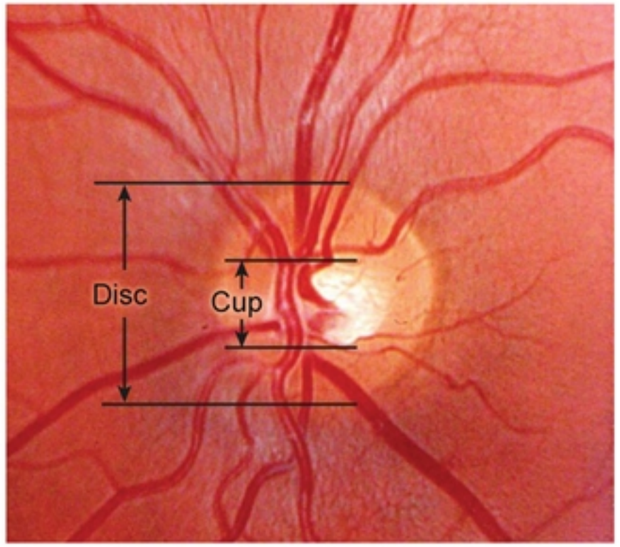	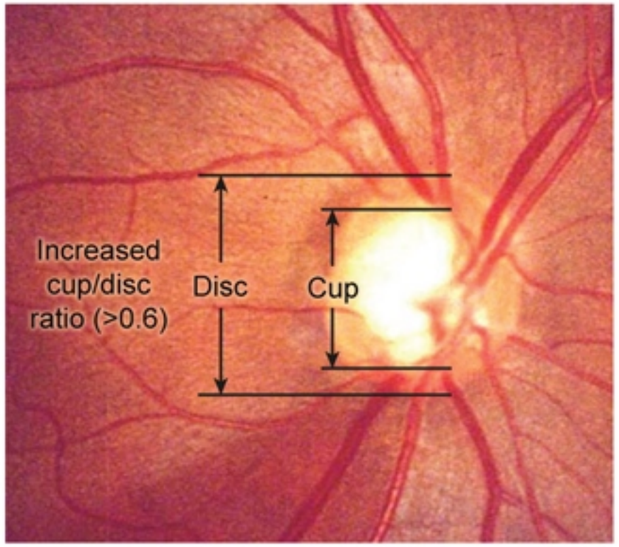
• Cup/disc ratio <0.5 • Clear disc rim	• Enlarged cup with cup/disc ratio >0.6 • Increase in cup size over time • Thinning of disc rim • Pale disc (optic nerve atrophy)

©UWorld

Zoom In Zoom Out Reset Add To Flash Card

- Retinitis pigmentosa.

1
2
3
4
5
6
7
8
9
10
11
12
13
14
15
16
17
18
19
20
21
22
23
24
25
26
27
28
29

Exhibit Display

Central retinal artery occlusion

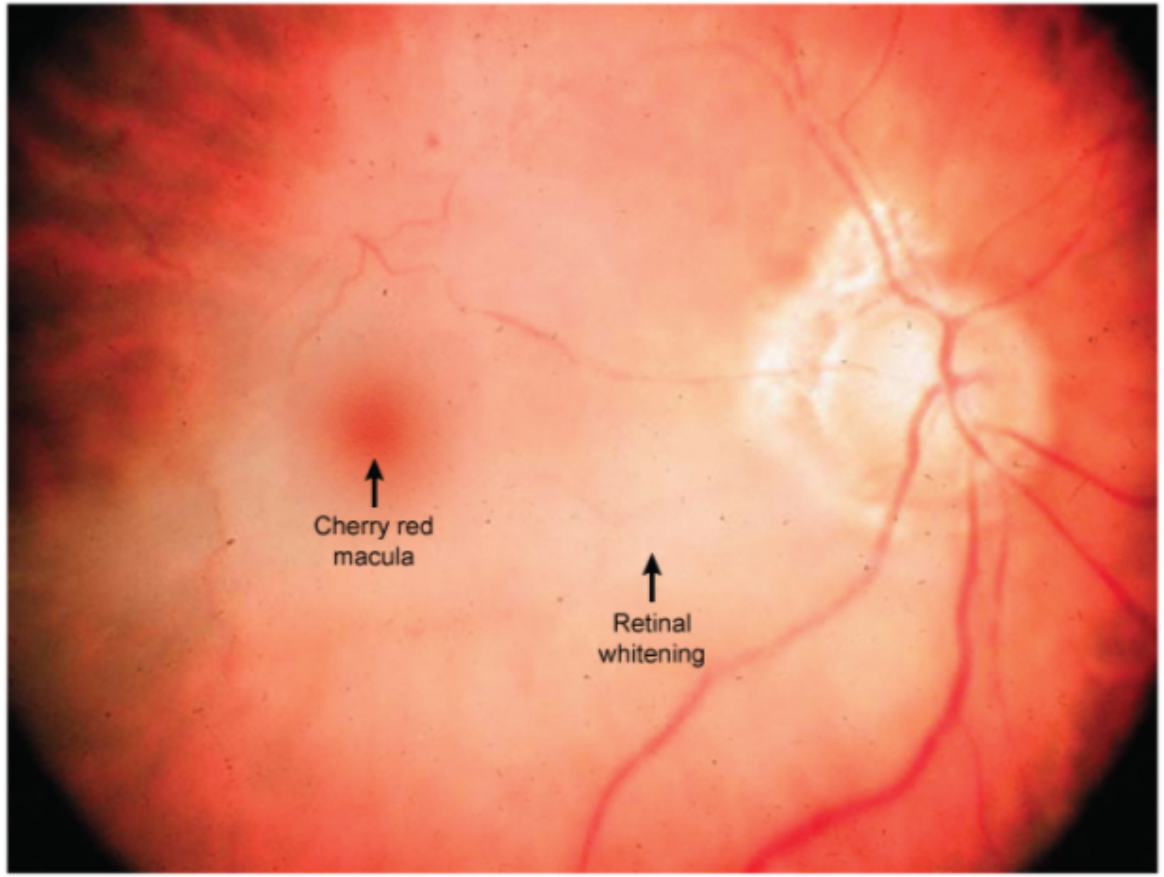

©UWorld

Zoom In
Zoom Out
Reset
Add To Flash Card

- Retinitis pigmentosa.

1
2
3
4
5
6
7
8
9
10
11
12
13
14
15
16
17
18
19
20
21
22
23
24
25
26
27
28
29

A 65-year-old man is evaluated for right lower extremity weakness and difficulty walking. The patient has a history of hypertension, type 2 diabetes mellitus, and osteoarthritis. He has smoked a pack of cigarettes daily for 30 years. During physical examination, the lateral border of his right sole is stroked using the blunt tip of a reflex hammer. The maneuver, starting near the heel and proceeding to the base of the fifth toe, elicits extension of the great toe and fanning out of the other toes. Which of the following additional findings is most likely to be observed in this patient's right lower extremity?

A. Decreased muscle girth compared to the left side

B. Increased briskness of deep tendon reflexes

C. Increased muscle rigidity with rhythmic interruptions

D. Pronounced weakness of extensor muscles compared to flexors

E. Spontaneous, intermittent contractions of muscle fibers

Submit

A 65-year-old man is evaluated for right lower extremity weakness and difficulty walking. The patient has a history of hypertension, type 2 diabetes mellitus, and osteoarthritis. He has smoked a pack of cigarettes daily for 30 years. During physical examination, the lateral border of his right sole is stroked using the blunt tip of a reflex hammer. The maneuver, starting near the heel and proceeding to the base of the fifth toe, elicits extension of the great toe and fanning out of the other toes. Which of the following additional findings is most likely to be observed in this patient's right lower extremity?

A. Decreased muscle girth compared to the left side (3%)

✓ B. Increased briskness of deep tendon reflexes (83%)

C. Increased muscle rigidity with rhythmic interruptions (5%)

D. Pronounced weakness of extensor muscles compared to flexors (2%)

E. Spontaneous, intermittent contractions of muscle fibers (5%)

Omitted
Correct answer
B

83%
Answered correctly

02 secs
Time Spent

01/14/2020
Last Updated

Explanation

1
2
3
4
5
6
7
8
9
10
11
12
13
14
15
16
17
18
19
20
21
22
23
24
25
26
27
28
29

Explanation

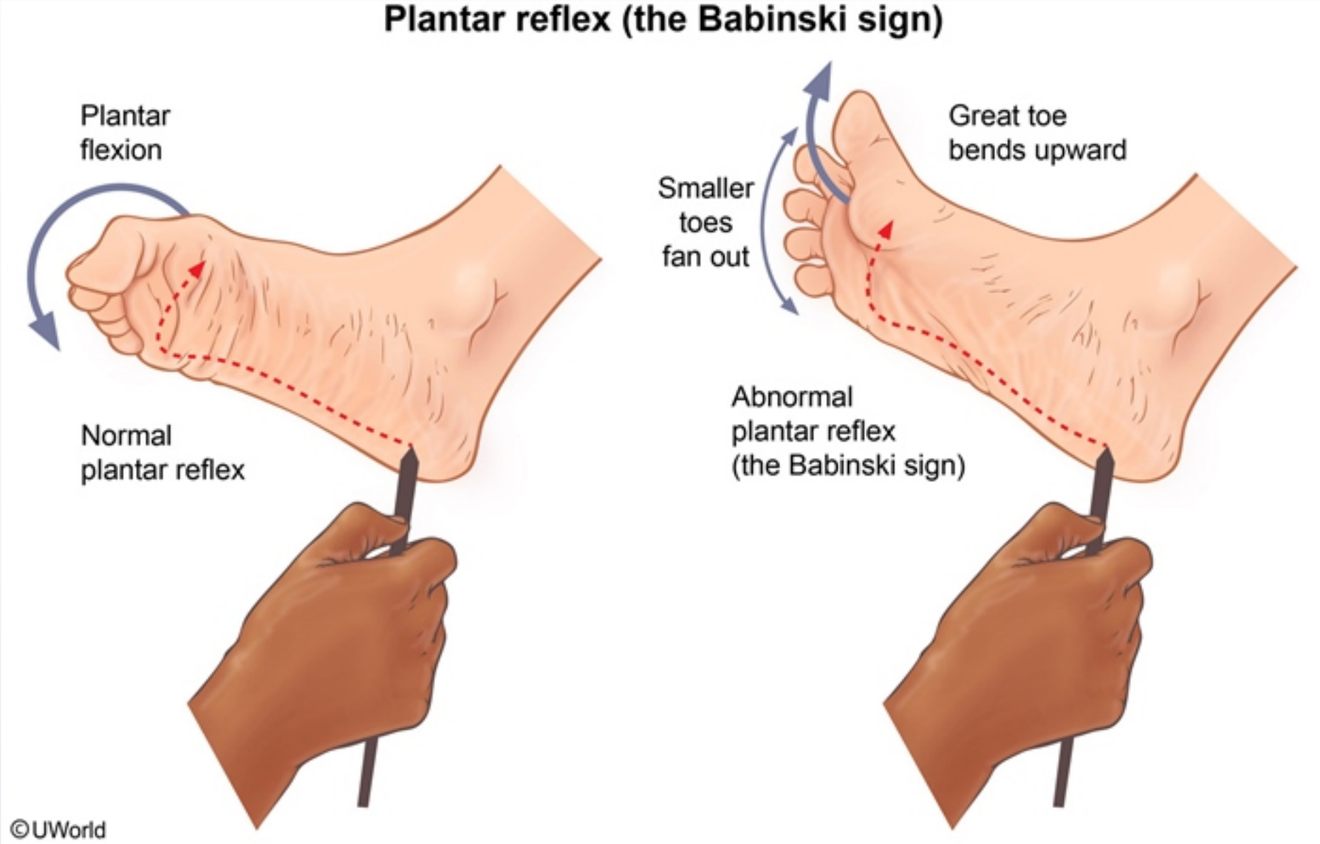

The **plantar reflex** (Babinski sign) is assessed by firmly stroking the plantar surface of the lateral foot from the heel to the ball. Plantar flexion of the toes is normal; **dorsiflexion** with or without fanning of the toes is considered abnormal and indicates an **upper motor neuron lesion**. Children age <12 months also exhibit a positive response, which is considered normal and reflects incomplete myelination of the corticospinal tract.

Upper motor neurons (UMNs) originate in the cerebral cortex and are responsible for the initiation of voluntary movement. UMN fibers travel through the brainstem and spinal cord to reach lower motor neurons (eg, cranial nerves, spinal nerves), which then innervate muscle fibers. UMN

©UWorld

The **plantar reflex** (Babinski sign) is assessed by firmly stroking the plantar surface of the lateral foot from the heel to the ball. Plantar flexion of the toes is normal; **dorsiflexion** with or without fanning of the toes is considered abnormal and indicates an **upper motor neuron lesion**. Children age <12 months also exhibit a positive response, which is considered normal and reflects incomplete myelination of the corticospinal tract.

Upper motor neurons (UMNs) originate in the cerebral cortex and are responsible for the initiation of voluntary movement. UMN fibers travel through the brainstem and spinal cord to reach lower motor neurons (eg, cranial nerves, spinal nerves), which then innervate muscle fibers. UMN injury can occur anywhere proximal to the anterior horn; common etiologies include stroke (which likely occurred in this patient with multiple risk factors), multiple sclerosis, or spinal cord transection.

Other signs of UMN injury include **hyperreflexia**, spastic paralysis, **increased muscle tone**, clasp-knife rigidity (increased muscle tension with sudden release on passive flexion), and **pyramidal weakness** (weakness is more pronounced in **lower extremity flexors** and **upper extremity extensors**). Upper extremity supination is also typically weaker than pronation, resulting in pronator drift.

(Choices A and E) Lower motor nerve lesions are most commonly due to trauma involving the peripheral nerves. Manifestations include muscle weakness/paralysis with hypotonia, suppressed or absent deep tendon reflexes, and muscle atrophy. Fasciculations (brief, spontaneous contractions of small groups of muscle fibers) also occur due to denervation of the affected muscles. However, the plantar reflex in lower motor lesions will be downgoing or indifferent (ie, no response).

(Choice C) Cogwheel rigidity (increased muscle rigidity with rhythmic interruptions noted on passive limb movement) is seen with lesions in the extrapyramidal tracts, which modulate motor neuron activity. This sign is classically seen in Parkinson disease.

(Choice D) In upper motor neuron lesions, lower extremity weakness is typically more pronounced in the flexors than the extensors.

Educational objective:
Upper motor neuron signs include abnormal plantar flexion (Babinski sign), spastic paralysis, increased muscle tone, clasp-knife rigidity, hyperreflexia, pronator drift, and pyramidal weakness (weakness more pronounced in lower extremity flexors and upper extremity extensors). Lower motor neuron signs include flaccid paralysis, weakness with hypotonia and muscle atrophy, fasciculations, and suppressed or absent reflexes.

tract.

Upper motor neurons (UMNs) originate in the cerebral cortex and are responsible for the initiation of voluntary movement. UMN fibers travel through the brainstem and spinal cord to reach lower motor neurons (eg, cranial nerves, spinal nerves), which then innervate muscle fibers. UMN injury can occur anywhere proximal to the anterior horn; common etiologies include stroke (which likely occurred in this patient with multiple risk factors), multiple sclerosis, or spinal cord transection.

Other signs of UMN injury include **hyperreflexia**, spastic paralysis, **increased muscle tone**, clasp-knife rigidity (increased muscle tension with sudden release on passive flexion), and **pyramidal weakness** (weakness is more pronounced in **lower extremity flexors** and **upper extremity extensors**). Upper extremity supination is also typically weaker than pronation, resulting in pronator drift.

(Choices A and E) Lower motor nerve lesions are most commonly due to trauma involving the peripheral nerves. Manifestations include muscle weakness/paralysis with hypotonia, suppressed or absent deep tendon reflexes, and muscle atrophy. Fasciculations (brief, spontaneous contractions of small groups of muscle fibers) also occur due to denervation of the affected muscles. However, the plantar reflex in lower motor lesions will be downgoing or indifferent (ie, no response).

(Choice C) Cogwheel rigidity (increased muscle rigidity with rhythmic interruptions noted on passive limb movement) is seen with lesions in the extrapyramidal tracts, which modulate motor neuron activity. This sign is classically seen in Parkinson disease.

(Choice D) In upper motor neuron lesions, lower extremity weakness is typically more pronounced in the flexors than the extensors.

Educational objective:
Upper motor neuron signs include abnormal plantar flexion (Babinski sign), spastic paralysis, increased muscle tone, clasp-knife rigidity, hyperreflexia, pronator drift, and pyramidal weakness (weakness more pronounced in lower extremity flexors and upper extremity extensors). Lower motor neuron signs include flaccid paralysis, weakness with hypotonia and muscle atrophy, fasciculations, and suppressed or absent reflexes.

Pathophysiology	Nervous System	Ischemic stroke
Subject	System	Topic

Copyright © UWorld. All rights reserved.

A 7-year-old girl is brought to the clinic due to nasal congestion with facial pain. The patient first developed congestion over a year ago. Her parents have been treating it with over-the-counter allergy medications, but there has been no improvement. Over the past 4 months, the congestion has worsened, and now the patient has difficulty breathing through her nose. She also developed a dry cough and a constant, dull pain over her cheeks. The patient's stools have been loose. Temperature is 37.8 C (100 F). Weight is at <1st percentile at 18 kg (39.7 lb), decreased from 19 kg (41.9 lb) 3 months ago. Examination reveals copious yellow mucus within both nares. Translucent, gray, shiny masses obscure the middle turbinates bilaterally. Lymphadenopathy is not present. The lungs have coarse breath sounds bilaterally. The abdomen is soft with no organomegaly. Which of the following is the most likely diagnosis?

A. Cystic fibrosis
B. HIV infection
C. Nasopharyngeal carcinoma
D. Primary ciliary dyskinesia
E. Seasonal allergic rhinitis

Submit

A 7-year-old girl is brought to the clinic due to nasal congestion with facial pain. The patient first developed congestion over a year ago. Her parents have been treating it with over-the-counter allergy medications, but there has been no improvement. Over the past 4 months, the congestion has worsened, and now the patient has difficulty breathing through her nose. She also developed a dry cough and a constant, dull pain over her cheeks. The patient's stools have been loose. Temperature is 37.8 C (100 F). Weight is at <1st percentile at 18 kg (39.7 lb), decreased from 19 kg (41.9 lb) 3 months ago. Examination reveals copious yellow mucus within both nares. Translucent, gray, shiny masses obscure the middle turbinates bilaterally. Lymphadenopathy is not present. The lungs have coarse breath sounds bilaterally. The abdomen is soft with no organomegaly. Which of the following is the most likely diagnosis?

- ✓ A. Cystic fibrosis (76%)
- B. HIV infection (0%)
- C. Nasopharyngeal carcinoma (5%)
- D. Primary ciliary dyskinesia (14%)
- E. Seasonal allergic rhinitis (2%)

Omitted
Correct answer
A

76%
Answered correctly

02 secs
Time Spent

07/07/2020
Last Updated

Explanation

Cystic fibrosis features

A 7-year-old girl is brought to the clinic due to nasal congestion with facial pain. The patient first developed congestion over a year ago. Her parents have been treating it with over-the-counter allergy medications, but there has been no improvement. Over the past 4 months, the congestion has worsened, and now the patient has difficulty breathing through her nose. She also developed a dry cough and a constant, dull pain over her cheeks. The patient's stools have been loose. Temperature is 37.8 C (100 F). Weight is at <1st percentile at 18 kg (39.7 lb), decreased from 19 kg (41.9 lb) 3 months ago. Examination reveals copious yellow mucus within both nares. Translucent, gray, shiny masses obscure the middle turbinates bilaterally. Lymphadenopathy is not present. The lungs have coarse breath sounds bilaterally. The abdomen is soft with no organomegaly. Which of the following is the most likely diagnosis?

- ✓ A. Cystic fibrosis (76%)
- B. HIV infection (0%)
- C. Nasopharyngeal carcinoma (5%)
- D. Primary ciliary dyskinesia (14%)
- E. Seasonal allergic rhinitis (2%)

Omitted
Correct answer
A

76%
Answered correctly

02 secs
Time Spent

07/07/2020
Last Updated

Explanation

Cystic fibrosis features

1
2
3
4
5
6
7
8
9
10
11
12
13
14
15
16
17
18
19
20
21
22
23
24
25
26
27
28
29

Cystic fibrosis features

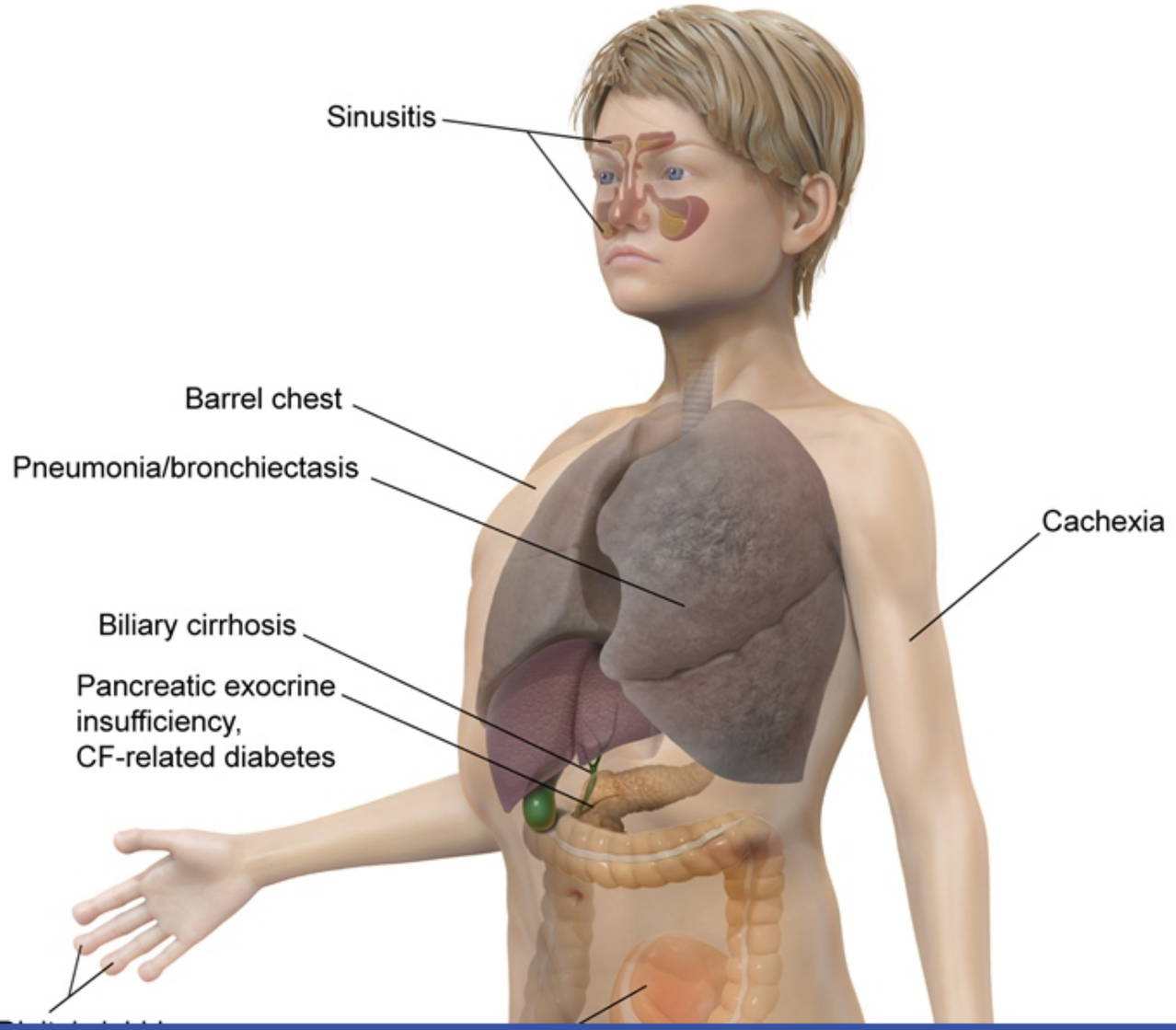

This patient has chronic rhinosinusitis with nasal polyposis and failure to thrive, findings concerning for **cystic fibrosis** (CF). CF is an inherited, multisystem disorder characterized by the abnormal transport of sodium and chloride due to a mutation in the *CFTR* gene. Although common CF mutations (eg, ΔF508) are often identified on newborn screening, less common mutations may go undetected and cause milder symptoms later in childhood.

Abnormal CFTR function causes thick, viscous respiratory secretions and impaired mucociliary clearance, leading to chronic sinopulmonary disease (eg, **chronic rhinosinusitis**). Patients typically have chronic cough, nasal congestion, and facial pain, as seen in this patient. Bilateral **nasal polyps**, benign outgrowths of inflamed mucosa, are also common due to chronic infection and present as nontender, shiny, gray masses in the nasal cavity or paranasal sinuses.

In CF, viscous secretions can also block pancreatic ducts, leading to **pancreatic insufficiency**. Decreased or absent pancreatic enzymes cause fat malabsorption with oily, **loose stools** and **failure to thrive** and/or **weight loss**. Over time, pancreatic injury can also lead to insufficient insulin production and CF-related diabetes.

(Choice B) HIV infection causes chronic infections and weight loss. However, without a known exposure (eg, blood transfusion), most pediatric HIV cases are transmitted perinatally; these patients typically develop symptoms by age 2, unlike this patient, who is age 7. In addition, nasal polyposis is rare with HIV.

(Choice C) Nasopharyngeal carcinoma presents with a nasopharyngeal mass that may cause facial pain and associated weight loss. However, the tumor is typically unilateral, and the diagnosis is usually in patients age >50.

(Choice D) Primary ciliary dyskinesia can present similarly to CF, with chronic rhinosinusitis and nasal polyposis due to impaired mucociliary clearance. However, failure to thrive and weight loss are not associated with this disorder.

(Choice E) Seasonal allergic rhinitis is a risk factor for developing sinus infections and nasal polyposis but would not cause weight loss.

Educational objective:
Chronic rhinosinusitis with nasal polyposis in children should prompt evaluation for cystic fibrosis, especially when signs of pancreatic insufficiency (eg, loose stools, failure to thrive, weight loss) are present.

References

- Paediatric nasal polyps in cystic fibrosis

A 48-year-old woman comes to the office due to an intermittent ear discharge over the last 2 years. She has also noticed decreased hearing in the right ear recently. Past medical history is significant for obesity, hyperlipidemia, seasonal allergies, and diet-controlled diabetes mellitus. Otoscopy shows a small perforation in the right tympanic membrane and a pearly mass behind the membrane. Conduction hearing loss is noted in the right ear. The remainder of the ear, nose, and throat examination is normal. Which of the following is the most likely cause of this patient's aural mass?

A. Cholesterol and lipid accumulation

B. Facial nerve neuroma

C. Malignant squamous cell neoplasm

D. Noncaseating granuloma

E. Squamous cell debris

Submit

A 48-year-old woman comes to the office due to an intermittent ear discharge over the last 2 years. She has also noticed decreased hearing in the right ear recently. Past medical history is significant for obesity, hyperlipidemia, seasonal allergies, and diet-controlled diabetes mellitus. Otoscopy shows a small perforation in the right tympanic membrane and a pearly mass behind the membrane. Conduction hearing loss is noted in the right ear. The remainder of the ear, nose, and throat examination is normal. Which of the following is the most likely cause of this patient's aural mass?

- A. Cholesterol and lipid accumulation (39%)
- B. Facial nerve neuroma (10%)
- C. Malignant squamous cell neoplasm (6%)
- D. Noncaseating granuloma (5%)
- ✓ E. Squamous cell debris (37%)

Omitted
Correct answer
E

37%
Answered correctly

02 secs
Time Spent

03/01/2020
Last Updated

Explanation

Cholesteatomas are collections of squamous cell debris that form a round, **pearly mass** behind the tympanic membrane in the middle ear. They can occur congenitally or may develop in adults as either an acquired primary lesion or secondary to infection, trauma, or surgery of the middle ear. Primary cholesteatomas are a result of chronic negative pressure in the middle ear causing retraction pockets in the tympanic membrane that become cystic; as the **squamous cell debris** accumulates, a cholesteatoma is formed. Secondary cholesteatomas occur after squamous epithelium migrates to or is implanted in the middle ear ("skin in the wrong place").

Cholesteatomas are collections of squamous cell debris that form a round, **pearly mass** behind the tympanic membrane in the middle ear. They can occur congenitally or may develop in adults as either an acquired primary lesion or secondary to infection, trauma, or surgery of the middle ear. Primary cholesteatomas are a result of chronic negative pressure in the middle ear causing retraction pockets in the tympanic membrane that become cystic; as the **squamous cell debris** accumulates, a cholesteatoma is formed. Secondary cholesteatomas occur after squamous epithelium migrates to or is implanted in the middle ear ("skin in the wrong place").

Cholesteatomas most commonly cause painless otorrhea. They also can produce lytic enzymes and are often discovered when they erode through the auditory ossicles, causing conductive **hearing loss**. If a mass grows sufficiently large, it can erode into the vestibular apparatus or facial nerve, causing vertigo or facial palsies.

(Choice A) Cholesterol granulomas can form in the middle ear after hemorrhage but are much less common than cholesteatomas. They appear as bluish-black gelatinous material behind the tympanic membrane. Despite what the name implies, cholesteatomas do not contain any lipid or cholesterol components.

(Choice B) A facial nerve neuroma can grow in the middle ear as the facial nerve courses through this territory. However, it would present with unilateral facial paralysis.

(Choice C) Squamous cell carcinoma is the most common malignant tumor of the ear canal. It typically appears as an ulcerated plaque or nodule. The most common symptom is local or regional pain.

(Choice D) Granulomatous disease of the ear can occur but is uncommon and usually develops in conjunction with a systemic disease, such as sarcoidosis, granulomatosis with polyangiitis, or Langerhans cell histiocytosis.

Educational objective:
Cholesteatomas are collections of squamous cell debris that form a mass behind the tympanic membrane. Cholesteatomas can be congenital or may occur as an acquired primary lesion or following infection, trauma, or surgery of the middle ear. They can cause hearing loss due to erosion into auditory ossicles.

References

- Updates and knowledge gaps in cholesteatoma research.

Pathophysiology Ear, Nose & Throat (ENT) Cholesteatoma

1
2
3
4
5
6
7
8
9
10
11
12
13
14
15
16
17
18
19
20
21
22
23
24
25
26
27
28
29

A 25-year-old woman comes to the hospital due to worsening dyspnea. The patient was previously healthy; 2 months ago, she delivered a healthy baby boy at 38 weeks gestation. Her arterial blood gas analysis shows evidence of hypoventilation. During further evaluation, she is asked to take several deep breaths, and the following physiologic information is obtained:

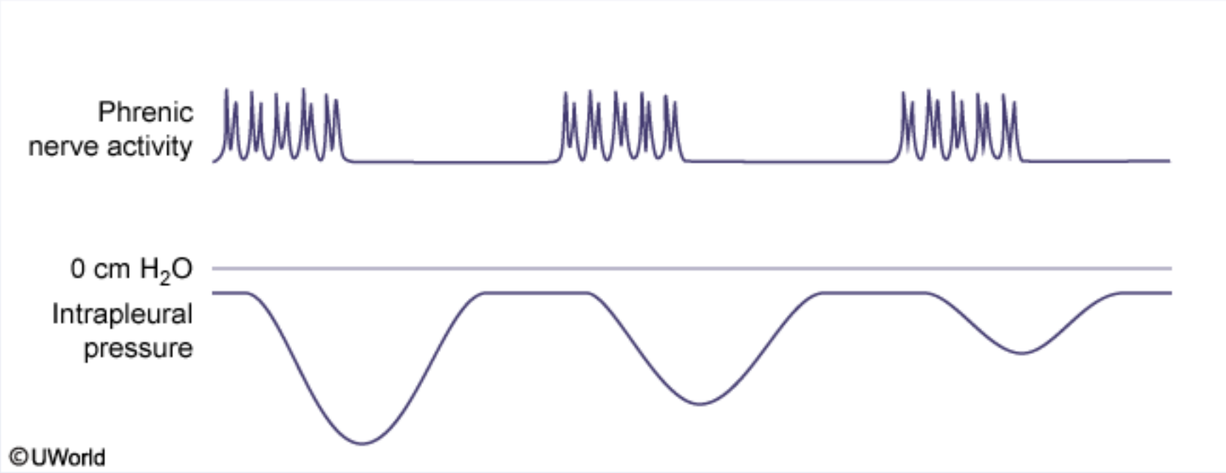

Which of the following locations is the most likely site of this patient's disease?

A. Brain stem
B. Nasopharynx
C. Neuromuscular junction
D. Pericardial space
E. Peripheral nerves

Submit

1 2 3 4 5 6 7 8 9 10 11 12 13 14 15 16 17 18 19 20 21 22 23 24 25 26 27 28 29

A 25-year-old woman comes to the hospital due to worsening dyspnea. The patient was previously healthy; 2 months ago, she delivered a healthy baby boy at 38 weeks gestation. Her arterial blood gas analysis shows evidence of hypoventilation. During further evaluation, she is asked to take several deep breaths, and the following physiologic information is obtained:

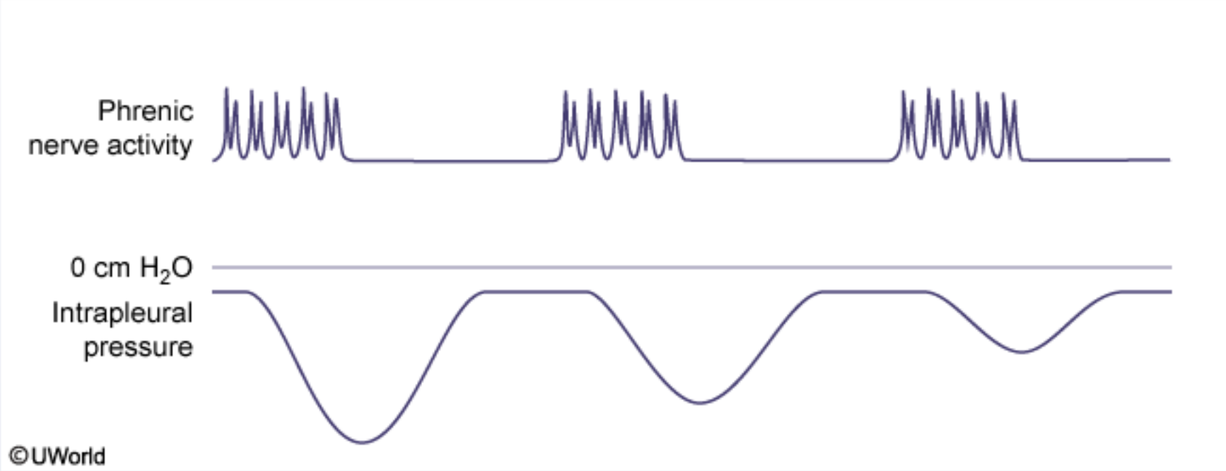

Which of the following locations is the most likely site of this patient's disease?

A. Brain stem
B. Nasopharynx
C. Neuromuscular junction
D. Pericardial space
E. Peripheral nerves

Submit

1 2 3 4 5 6 7 8 9 10 11 12 13 14 15 16 17 18 19 20 21 22 23 24 25 26 27 28 29

A 25-year-old woman comes to the hospital due to worsening dyspnea. The patient was previously healthy; 2 months ago, she delivered a healthy baby boy at 38 weeks gestation. Her arterial blood gas analysis shows evidence of hypoventilation. During further evaluation, she is asked to take several deep breaths, and the following physiologic information is obtained:

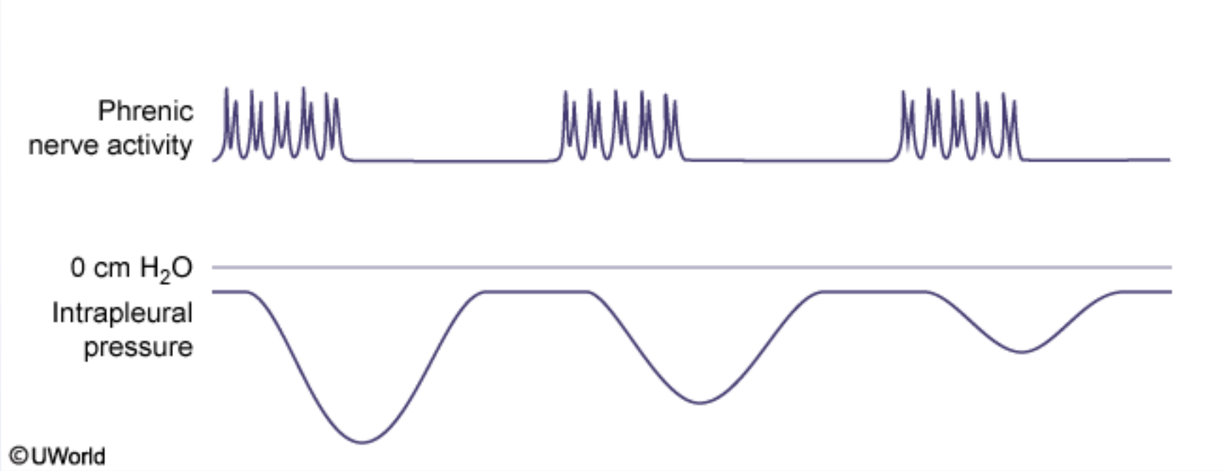

Which of the following locations is the most likely site of this patient's disease?

- A. Brain stem (20%)
- B. Nasopharynx (3%)
- ✓ C. Neuromuscular junction (57%)
- D. Pericardial space (9%)
- E. Peripheral nerves (8%)

Omitted
Correct answer

57%
Answered correctly

05 secs
Time Spent

02/21/2020
Last Updated

Intrapleural pressure (ie, between the lung and chest wall pleura) is slightly negative at rest due to the inward elastic recoil of the lungs and outward recoil of the chest wall. **During inspiration**, diaphragmatic contraction is primarily responsible for creating a **more negative intrapleural pressure** that causes expansion of the thoracic cavity, drawing air into the lungs. Passive expiration occurs with respiratory muscle relaxation and relies on the natural inward elastic recoil of the lungs to expel air as the intrapleural pressure returns to baseline.

The graph shows **progressive attenuation** of the intrapleural pressure change that occurs during deep, repetitive inspiration. Because there is no apparent decrement in phrenic nerve activity, this patient's progressively weaker diaphragmatic contractions are likely due to excessive skeletal muscle fatigue (eg, severe obstructive or restrictive lung disease) or impaired neuromuscular transmission. In **myasthenia gravis**, autoantibodies against postsynaptic acetylcholine receptors cause fatigable skeletal muscle weakness as **acetylcholine stores** within the presynaptic nerve terminal become progressively **depleted** with repetitive stimulation. Women in the postpartum period (like this patient) are at particularly high risk of developing myasthenia gravis.

(Choice A) Impairment of the respiratory control centers in the brain stem can result in decreased frequency and/or amplitude of involuntary respirations (Ondine curse). Voluntary breathing would be unaffected.

(Choice B) Nasopharyngeal lesions are unlikely to cause inspiratory airflow obstruction severe enough to cause rapid diaphragmatic fatigue as the oropharynx remains unobstructed (allowing the patient to breath from the mouth).

(Choices D and E) Metastatic disease to the pericardium could compress the phrenic nerve due to its location along the pericardium. In addition, the phrenic nerve can be affected by a peripheral neuropathy. However, both diseases cause uniform weak inspirations during maximal voluntary ventilation rather than progressively weaker diaphragmatic contractions.

Educational objective:
Progressively weakening diaphragmatic contractions during maximal voluntary ventilation with intact phrenic nerve stimulation indicate neuromuscular junction pathology (eg, myasthenia gravis) and/or abnormally rapid diaphragmatic muscle fatigue (eg, restrictive lung or chest wall disease).

Pathophysiology	Nervous System	Myasthenia gravis
Subject	System	Topic

1
2
3
4
5
6
7
8
9
10
11
12
13
14
15
16
17
18
19
20
21
22
23
24
25
26
27
28
29

A 42-year-old woman comes to the office to discuss dizziness. She has a 6-month history of episodic bouts of a "spinning sensation" associated with nausea and ringing in her left ear. The patient also has difficulty hearing while holding her phone to the left ear, although hearing in her right ear is normal. The dizziness improves spontaneously and she feels "fine" between episodes. Past medical history is notable for hypothyroidism, for which she is on thyroid replacement therapy, and endometriosis, which led to a hysterectomy at age 38. The patient works as a supermarket manager. She does not use tobacco or drink alcohol. The patient's condition is most likely the result of which of the following?

A. Demyelinating process in the central nervous system

B. Increased volume of endolymph in the inner ear

C. Inflammation of the vestibular labyrinth

D. Mass lesion at the cerebellopontine angle

E. Sclerosis of the ossicles

Submit

A 42-year-old woman comes to the office to discuss dizziness. She has a 6-month history of episodic bouts of a "spinning sensation" associated with nausea and ringing in her left ear. The patient also has difficulty hearing while holding her phone to the left ear, although hearing in her right ear is normal. The dizziness improves spontaneously and she feels "fine" between episodes. Past medical history is notable for hypothyroidism, for which she is on thyroid replacement therapy, and endometriosis, which led to a hysterectomy at age 38. The patient works as a supermarket manager. She does not use tobacco or drink alcohol. The patient's condition is most likely the result of which of the following?

- A. Demyelinating process in the central nervous system (6%)
- ✓ B. Increased volume of endolymph in the inner ear (54%)
- C. Inflammation of the vestibular labyrinth (18%)
- D. Mass lesion at the cerebellopontine angle (16%)
- E. Sclerosis of the ossicles (4%)

Omitted
Correct answer
B

54%
Answered correctly

02 secs
Time Spent

04/25/2020
Last Updated

Explanation

Common causes of vertigo		
	Cause	Features

1
2
3
4
5
6
7
8
9
10
11
12
13
14
15
16
17
18
19
20
21
22
23
24
25
26
27
28
29

Common causes of vertigo

	Cause	Features
Ménière disease	• Increased pressure & volume of endolymph	• Recurrent vertigo • Ear fullness/pain • Unilateral **hearing loss & tinnitus**
BPPV	• Otoliths in semicircular canals	• Brief episodes brought on by **head movement** • No auditory symptoms
Vestibular neuritis (labyrinthitis)	• Inflammation of vestibular nerve (viral or postviral)	• **Single episode** that can last days • Severe vertigo but no hearing loss

BPPV = benign paroxysmal positional vertigo.

©UWorld

This patient has **Ménière disease**, a disorder of the inner ear characterized by increased volume and pressure of endolymph (**endolymphatic hydrops**) that is thought to be due to defective resorption of endolymph. The resultant distension of the endolymphatic system causes damage to the vestibular and cochlear components of the inner ear. Ménière disease is characterized by the following triad:

1. Low-frequency **tinnitus**, or ringing, in the affected ear, often accompanied by a feeling of fullness
2. **Vertigo**, the subjective sensation of spinning or motion in the absence of actual motion; commonly associated with lightheadedness, nausea, and vomiting
3. **Sensorineural hearing loss**, which is variable in severity but usually worsens over time

(Choice A) Multiple sclerosis (MS) is characterized by patchy demyelination in the central nervous system that varies over time. The presentation

This patient has **Ménière disease**, a disorder of the inner ear characterized by increased volume and pressure of endolymph (**endolymphatic hydrops**) that is thought to be due to defective resorption of endolymph. The resultant distension of the endolymphatic system causes damage to the vestibular and cochlear components of the inner ear. Ménière disease is characterized by the following triad:

1. Low-frequency **tinnitus**, or ringing, in the affected ear, often accompanied by a feeling of fullness
2. **Vertigo**, the subjective sensation of spinning or motion in the absence of actual motion; commonly associated with lightheadedness, nausea, and vomiting
3. **Sensorineural hearing loss**, which is variable in severity but usually worsens over time

(Choice A) Multiple sclerosis (MS) is characterized by patchy demyelination in the central nervous system that varies over time. The presentation of MS is highly variable and may resemble Ménière disease, but most patients will have additional, extra-auditory symptoms (eg, visual symptoms, sensory disruptions).

(Choice C) Labyrinthitis is inflammation of the vestibular nerve that causes acute-onset vertigo, nausea, and vomiting. It usually occurs in a single episode following a viral syndrome.

(Choice D) A mass lesion at the cerebellopontine angle is most commonly an acoustic neuroma (schwannoma of CN VIII). An acoustic neuroma could cause sensorineural hearing loss, vertigo, and tinnitus, but symptoms would be persistent and progressive rather than episodic.

(Choice E) Otosclerosis is an inherited condition seen in middle age. Patients present with conductive hearing loss due to bony overgrowth of the footplate of the stapes. Vertigo does not occur.

Educational objective:
Ménière disease is characterized by tinnitus, vertigo, and sensorineural hearing loss. Its pathogenesis is related to an increased volume and pressure of endolymph in the vestibular apparatus.

References

- Endolymphatic hydrops: pathophysiology and experimental models.

Pathophysiology	Ear, Nose & Throat (ENT)	Meniere disease
Subject	System	Topic

Copyright © UWorld. All rights reserved.

1
2
3
4
5
6
7
8
9
10
11
12
13
14
15
16
17
18
19
20
21
22
23
24
25
26
27
28
29

Electric stimulation of the musculocutaneous nerve causes a rapid twitch of the biceps muscle. Electron microscopy shows numerous vesicles within the musculocutaneous nerve terminals. In order for these vesicles to release their contents into the synaptic cleft, which of the following substances is required?

A. Sodium
B. Calcium
C. cAMP
D. IP3
E. DAG
F. cGMP

Submit

Electric stimulation of the musculocutaneous nerve causes a rapid twitch of the biceps muscle. Electron microscopy shows numerous vesicles within the musculocutaneous nerve terminals. In order for these vesicles to release their contents into the synaptic cleft, which of the following substances is required?

- A. Sodium (3%)
- ✓ B. Calcium (89%)
- C. cAMP (3%)
- D. IP3 (2%)
- E. DAG (0%)
- F. cGMP (0%)

Omitted
Correct answer
B

89%
Answered correctly

03 secs
Time Spent

02/03/2020
Last Updated

Explanation

The synaptic vesicles in motor neuron presynaptic terminals contain acetylcholine (ACh). When an action potential depolarizes the presynaptic terminal membrane, voltage-gated calcium channels open, causing an influx of extracellular calcium into the synaptic terminal. This calcium current stimulates fusion of the presynaptic vesicles with the plasma membrane and exocytosis of ACh. The nicotinic ACh receptors on the postsynaptic skeletal muscle end plate are ligand-gated sodium and potassium ion channels. The increased sodium and potassium conductance that occurs with ACh binding generates a motor end plate potential that signals for depolarization of the muscle cell membrane. ACh in the

Omitted
Correct answer
B

89%
Answered correctly

03 secs
Time Spent

02/03/2020
Last Updated

Explanation

The synaptic vesicles in motor neuron presynaptic terminals contain acetylcholine (ACh). When an action potential depolarizes the presynaptic terminal membrane, voltage-gated calcium channels open, causing an influx of extracellular calcium into the synaptic terminal. This calcium current stimulates fusion of the presynaptic vesicles with the plasma membrane and exocytosis of ACh. The nicotinic ACh receptors on the postsynaptic skeletal muscle end plate are ligand-gated sodium and potassium ion channels. The increased sodium and potassium conductance that occurs with ACh binding generates a motor end plate potential that signals for depolarization of the muscle cell membrane. ACh in the synaptic cleft is degraded by acetylcholinesterase.

(Choice A) Rapid sodium influx is responsible for the upstroke of the action potential in skeletal muscle, smooth muscle, cardiac muscle and Purkinje fibers. In contrast, the initial upstroke of the action potential in the SA node depends on calcium influx.

(Choices C- F) Second messengers do not play a role in the release of synaptic vesicle contents (ACh) at the neuromuscular junction.

Educational Objective:
Acetylcholine release from presynaptic terminal vesicles at the neuromuscular junction depends upon the influx of extracellular calcium into the presynaptic terminal. Calcium influx into the nerve terminal occurs following neuronal depolarization and opening of voltage-gated calcium channels.

Pathophysiology	Nervous System	Neuromuscular junction
Subject	System	Topic

Copyright © UWorld. All rights reserved.

1
2
3
4
5
6
7
8
9
10
11
12
13
14
15
16
17
18
19
20
21
22
23
24
25
26
27
28
29

A 65-year-old male complains of bilateral visual difficulty that has progressed over the last year. Funduscopy reveals small yellow retinal lesions clustered in the macula. Which of the following would you expect most on visual field examination?

- A. Homonymous hemianopsia
- B. Binasal hemianopsia
- C. Bitemporal hemianopsia
- D. Arcuate scotomas
- E. Central scotomas

Submit

A 65-year-old male complains of bilateral visual difficulty that has progressed over the last year. Funduscopy reveals small yellow retinal lesions clustered in the macula. Which of the following would you expect most on visual field examination?

- A. Homonymous hemianopsia (2%)
- B. Binasal hemianopsia (1%)
- C. Bitemporal hemianopsia (5%)
- D. Arcuate scotomas (7%)
- ✓ E. Central scotomas (81%)

Omitted
Correct answer
E

81%
Answered correctly

02 secs
Time Spent

02/03/2020
Last Updated

Explanation

The macula is a yellowish spot approximately 1.5 mm in diameter located near the center of the retina. It is characterized histologically by the presence of densely packed cones, few overlying cells and no blood vessels. Each macular cone synapses to a single bipolar cell, which, in turn, synapses to a single ganglion cell. Due to this arrangement the visual acuity in the macula, and particularly the fovea, is greater than in any other area of the retina. The neural fibers that serve the macula transmit to an area of the occipital visual cortex that is separate from the area of representation of the peripheral fields (this area is also relatively large in size). Due to this peculiar cortical representation, macular sparing is common in lesions of the occipital cortex.

Macular lesions impair central vision and result in central scotomata **(Choice E)**. The term **scotoma** refers to any visual defect surrounded by a

The macula is a yellowish spot approximately 1.5 mm in diameter located near the center of the retina. It is characterized histologically by the presence of densely packed cones, few overlying cells and no blood vessels. Each macular cone synapses to a single bipolar cell, which, in turn, synapses to a single ganglion cell. Due to this arrangement the visual acuity in the macula, and particularly the fovea, is greater than in any other area of the retina. The neural fibers that serve the macula transmit to an area of the occipital visual cortex that is separate from the area of representation of the peripheral fields (this area is also relatively large in size). Due to this peculiar cortical representation, macular sparing is common in lesions of the occipital cortex.

Macular lesions impair central vision and result in central scotomata **(Choice E)**. The term **scotoma** refers to any visual defect surrounded by a relatively unimpaired field of vision. Scotomas occur due to pathologic processes that involve parts of the retina or optic nerve. Examples of such processes include demyelinating diseases such as multiple sclerosis, diabetic retinopathy and retinitis pigmentosa. Pathologic processes that involve the entire optic nerve lead to monocular blindness.

The patient described in this clinical vignette is likely to have macular degeneration (MD). This disorder is frequently age-related, and is the most common cause of blindness in people over 50 years old in the US. Macular degeneration is characterized by progressive loss of central vision due to deposition of fatty tissue (drusen) behind the retina (dry MD) and neovascularization of the retina (wet MD).

(Choice A) Homonymous hemianopsia is a loss of vision in the same side of the visual field in both eyes. It occurs due to transection of the contralateral optic tract, the fibers of the visual pathway linking the optic chiasm to the lateral geniculate body.

(Choice B) Binasal hemianopsia is a loss of vision in the nasal fields of both eyes. It is caused by pressure to the lateral areas of the optic chiasm. This may result from calcified carotid arteries.

(Choice C) Bitemporal hemianopsia is a loss of vision in the temporal fields of both eyes. It is caused by compression of the medial part of the optic chiasm, where the nasal fibers decussate, most commonly by a pituitary adenoma.

(Choice D) Arcuate scotomas occur due to damage to a particular region of the optic nerve head. The resulting visual field defect follows the arcuate shape of the nerve fiber pattern.

Educational Objective:
A scotoma is a visual field defect that occurs due to a pathologic process that involves parts of the retina or the optic nerve resulting in a discrete area of altered vision surrounded by zones of normal vision. Lesions of the macula cause central scotomas.

common in lesions of the occipital cortex.

Macular lesions impair central vision and result in central scotomata **(Choice E)**. The term **scotoma** refers to any visual defect surrounded by a relatively unimpaired field of vision. Scotomas occur due to pathologic processes that involve parts of the retina or optic nerve. Examples of such processes include demyelinating diseases such as multiple sclerosis, diabetic retinopathy and retinitis pigmentosa. Pathologic processes that involve the entire optic nerve lead to monocular blindness.

The patient described in this clinical vignette is likely to have macular degeneration (MD). This disorder is frequently age-related, and is the most common cause of blindness in people over 50 years old in the US. Macular degeneration is characterized by progressive loss of central vision due to deposition of fatty tissue (drusen) behind the retina (dry MD) and neovascularization of the retina (wet MD).

(Choice A) Homonymous hemianopsia is a loss of vision in the same side of the visual field in both eyes. It occurs due to transection of the contralateral optic tract, the fibers of the visual pathway linking the optic chiasm to the lateral geniculate body.

(Choice B) Binasal hemianopsia is a loss of vision in the nasal fields of both eyes. It is caused by pressure to the lateral areas of the optic chiasm. This may result from calcified carotid arteries.

(Choice C) Bitemporal hemianopsia is a loss of vision in the temporal fields of both eyes. It is caused by compression of the medial part of the optic chiasm, where the nasal fibers decussate, most commonly by a pituitary adenoma.

(Choice D) Arcuate scotomas occur due to damage to a particular region of the optic nerve head. The resulting visual field defect follows the arcuate shape of the nerve fiber pattern.

Educational Objective:
A scotoma is a visual field defect that occurs due to a pathologic process that involves parts of the retina or the optic nerve resulting in a discrete area of altered vision surrounded by zones of normal vision. Lesions of the macula cause central scotomas.

Pathophysiology	Ophthalmology	Macular degeneration
Subject	System	Topic

Copyright © UWorld. All rights reserved.

A 6-month-old girl is brought to the clinic for routine care. She has not had any illnesses, although the mother says that the girl has trouble latching when breast feeding. She can roll over when prone but cannot roll from the supine position or sit unsupported. The infant was born vaginally after an uncomplicated pregnancy. Vital signs are within normal limits. On physical examination, the girl has a head circumference above the 97th percentile for her age and a full anterior fontanelle. The remainder of her physical examination is unremarkable. At birth, the girl's head circumference was at the 50th percentile. CT scan of the head reveals significant dilation of the lateral ventricles. If this condition is left uncorrected, which of the following is the most likely complication that will be seen in this patient?

A. Infection

B. Lower extremity hyporeflexia

C. Muscle hypertonicity

D. Subarachnoid hemorrhage

E. Tumor

Submit

A 6-month-old girl is brought to the clinic for routine care. She has not had any illnesses, although the mother says that the girl has trouble latching when breast feeding. She can roll over when prone but cannot roll from the supine position or sit unsupported. The infant was born vaginally after an uncomplicated pregnancy. Vital signs are within normal limits. On physical examination, the girl has a head circumference above the 97th percentile for her age and a full anterior fontanelle. The remainder of her physical examination is unremarkable. At birth, the girl's head circumference was at the 50th percentile. CT scan of the head reveals significant dilation of the lateral ventricles. If this condition is left uncorrected, which of the following is the most likely complication that will be seen in this patient?

- A. Infection (4%)
- B. Lower extremity hyporeflexia (20%)
- ✓ C. Muscle hypertonicity (60%)
- D. Subarachnoid hemorrhage (12%)
- E. Tumor (1%)

Omitted
Correct answer
C

60%
Answered correctly

02 secs
Time Spent

05/20/2020
Last Updated

Explanation

Congenital hydrocephalus	
	• Congenital obstruction (eg, aqueductal stenosis,

Congenital hydrocephalus	
Causes	• Congenital obstruction (eg, aqueductal stenosis, Chiari malformation) • Acquired obstruction (eg, congenital infection, posthemorrhagic)
Symptoms	• Macrocephaly • Bulging fontanelle • Poor feeding • Developmental delay • Spasticity & hyperreflexia
Treatment	• Cerebral shunting (ie, ventriculoperitoneal shunt)

©UWorld

Hydrocephalus is caused by abnormal accumulation of cerebrospinal fluid (CSF) in the brain. It is due to either overproduction or **impaired drainage** of CSF. Congenital hydrocephalus results from a structural malformation that causes impaired CSF drainage (eg, aqueductal stenosis, Chiari malformations, Dandy-Walker syndrome). Obstruction can also be secondary to infection (eg, cytomegalovirus, toxoplasmosis, meningitis) or intraventricular hemorrhage. Hydrocephalus must be distinguished from hydrocephalus ex-vacuo, which is normal CSF expansion following cerebral volume loss rather than abnormal CSF accumulation.

Infants with hydrocephalus typically develop **macrocephaly**, poor feeding, **muscle hypertonicity**, and hyperreflexia. Hypertonicity and hyperreflexia result from **upper motor neuron injury** caused by stretching of the periventricular pyramidal tracts. Untreated hydrocephalus can lead to developmental delay and seizures. Treatment requires surgical placement of a **shunt** to bypass the obstruction, most often via the ventriculoperitoneal route.

	• Spasticity & hyperreflexia
Treatment	• Cerebral shunting (ie, ventriculoperitoneal shunt)

©UWorld

Hydrocephalus is caused by abnormal accumulation of cerebrospinal fluid (CSF) in the brain. It is due to either overproduction or **impaired drainage** of CSF. Congenital hydrocephalus results from a structural malformation that causes impaired CSF drainage (eg, aqueductal stenosis, Chiari malformations, Dandy-Walker syndrome). Obstruction can also be secondary to infection (eg, cytomegalovirus, toxoplasmosis, meningitis) or intraventricular hemorrhage. Hydrocephalus must be distinguished from hydrocephalus ex-vacuo, which is normal CSF expansion following cerebral volume loss rather than abnormal CSF accumulation.

Infants with hydrocephalus typically develop **macrocephaly**, poor feeding, **muscle hypertonicity**, and hyperreflexia. Hypertonicity and hyperreflexia result from **upper motor neuron injury** caused by stretching of the periventricular pyramidal tracts. Untreated hydrocephalus can lead to developmental delay and seizures. Treatment requires surgical placement of a **shunt** to bypass the obstruction, most often via the ventriculoperitoneal route.

(Choices A, D, and E) Infection, hemorrhage, and cancer do not result from hydrocephalus but are instead potential causes of acquired hydrocephalus.

(Choice B) Lower extremity hyporeflexia would result from damage to the lower motor neurons, which can occur in poliomyelitis or spinal muscular atrophy.

Educational objective:
Hydrocephalus in infants presents with macrocephaly and poor feeding. Imaging studies showing enlarged ventricles are characteristic. Untreated hydrocephalus leads to spasticity due to stretching of the periventricular pyramidal tracts, developmental delays, and seizures.

Pathophysiology	Nervous System	Hydrocephalus
Subject	System	Topic

Copyright © UWorld. All rights reserved.

1
2
3
4
5
6
7
8
9
10
11
12
13
14
15
16
17
18
19
20
21
22
23
24
25
26
27
28
29

A 54-year-old hospitalized man develops new-onset slurring of speech and extremity weakness. Medical history is significant for alcohol abuse. Physical examination reveals confusion, dysarthria, dysphagia, and quadriparesis. MRI of the brain shows symmetric areas of demyelination in the pons. Which of the following most likely predisposed this patient to his current condition?

A. Atheroma formation in the vertebrobasilar arteries

B. Hematogenous dissemination of microbial agents

C. Nutritional deficiency of water-soluble vitamin

D. Overly rapid correction of electrolyte abnormalities

E. Paraneoplastic production of anti-neuronal antibodies

Submit

A 54-year-old hospitalized man develops new-onset slurring of speech and extremity weakness. Medical history is significant for alcohol abuse. Physical examination reveals confusion, dysarthria, dysphagia, and quadriparesis. MRI of the brain shows symmetric areas of demyelination in the pons. Which of the following most likely predisposed this patient to his current condition?

- A. Atheroma formation in the vertebrobasilar arteries (1%)
- B. Hematogenous dissemination of microbial agents (0%)
- C. Nutritional deficiency of water-soluble vitamin (23%)
- ✓ D. Overly rapid correction of electrolyte abnormalities (74%)
- E. Paraneoplastic production of anti-neuronal antibodies (0%)

Omitted
Correct answer
D

74%
Answered correctly

02 secs
Time Spent

03/29/2020
Last Updated

Explanation

Osmotic demyelination syndrome

Normonatremia

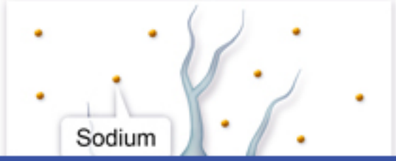

1
2
3
4
5
6
7
8
9
10
11
12
13
14
15
16
17
18
19
20
21
22
23
24
25
26
27
28
29

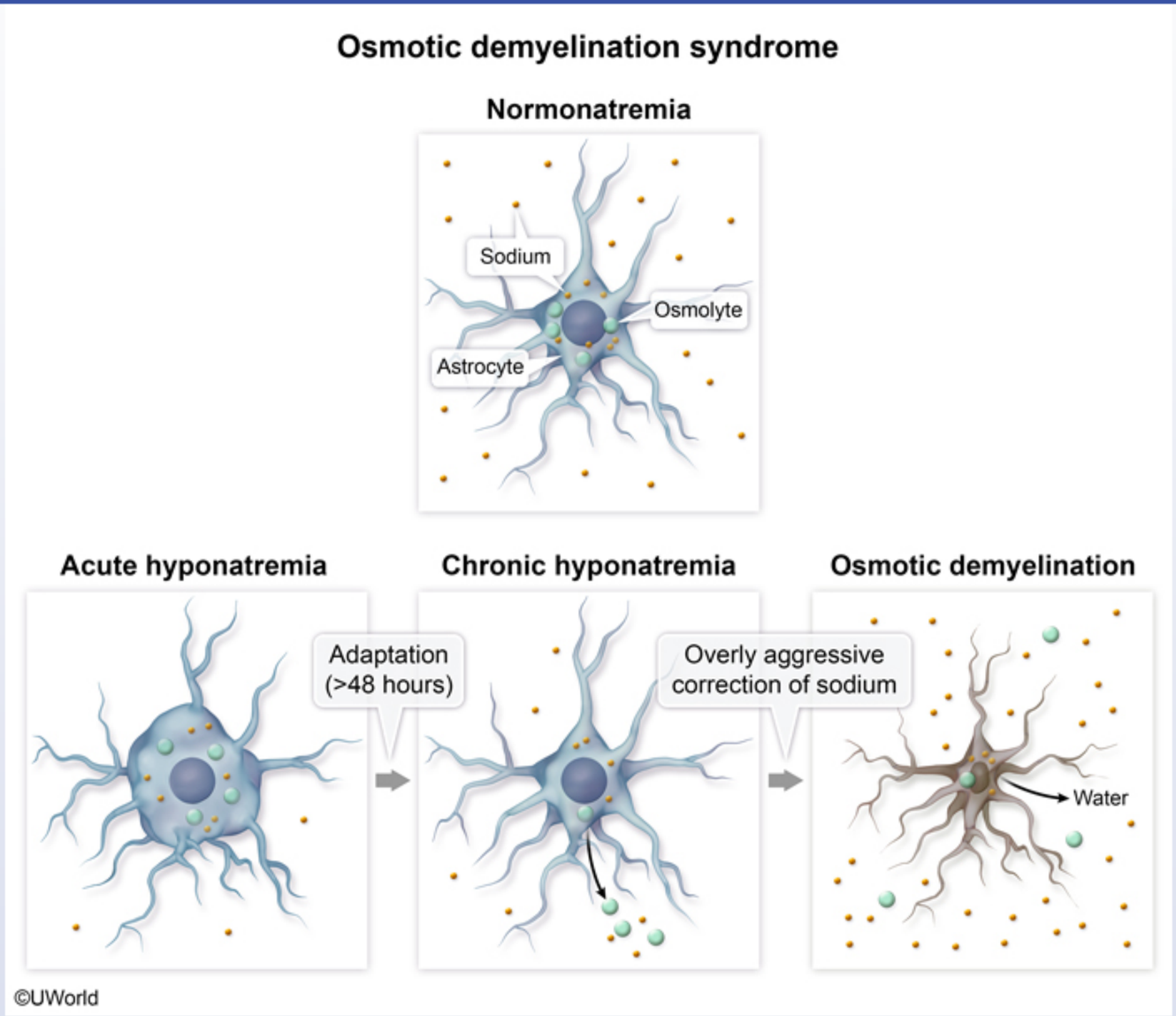

This patient with a history of alcohol abuse has new-onset **pseudobulbar palsy** (dysarthria, dysphagia, dysphonia) and **quadriparesis**

This patient with a history of alcohol abuse has new-onset **pseudobulbar palsy** (dysarthria, dysphagia, dysphonia) and **quadriparesis** suggesting a brainstem insult. In association with the focal, symmetric **demyelination of the pons** noted on MRI, this presentation suggests **osmotic demyelination syndrome** (ODS), also known as central pontine myelinolysis. Other classic clinical features include a horizontal gaze paralysis, obtundation, and "locked in" syndrome, in which patients are aware but unable to move or communicate verbally.

Decreased plasma osmolality from hyponatremia (common in patients with alcohol abuse) results in water flowing across the osmotic gradient into brain cells; if this happens acutely, life-threatening cerebral edema can occur. However, with slowly developing (chronic) hyponatremia, astrocytes and oligodendrocytes excrete osmotically active organic solutes (eg, glutamate, myoinositol) to cause compensatory intracellular water loss and normalization of brain volume. Therefore, chronic hyponatremia can present with minimal neurologic symptoms.

However, **overly rapid correction of chronic hyponatremia** (eg, bolus of normal saline) reverses the osmotic gradient, drawing water from the cells into the plasma. The astrocytes and oligodendrocytes are unable to rapidly re-accumulate the lost organic solutes, resulting in cell shrinkage, dehydration, and apoptosis. The resultant demyelination preferentially affects the pons, possibly because the cells there are less metabolically active and less able to rapidly regenerate organic solutes.

(Choice A) Vertebrobasilar atheroma formation can result in a pontine stroke with similar symptoms; however, ischemia (not demyelination) is expected on MRI.

(Choice B) Septic emboli (hematogenous spread of bacteria or fungi) are typically associated with endocarditis. Symptomatic brain abscesses can occur (eg, headache, focal neurologic findings), but MRI would demonstrate ring enhancement with vasogenic edema.

(Choice C) The administration of glucose-containing fluids to patients with thiamine deficiency (common in patients with alcohol abuse) can cause Wernicke encephalopathy (ie, ataxia, oculomotor dysfunction, encephalopathy). Korsakoff syndrome (chronic memory impairment) can also occur. Mamillary body atrophy is often visible on MRI.

(Choice E) Paraneoplastic production of anti-neuronal antibodies can be seen in a variety of malignancies (eg, small cell lung cancer, thymoma), but symptoms are often nonfocal (eg, altered mentation, seizures). Demyelination is unexpected.

Educational objective:
Osmotic demyelination syndrome results from overly rapid correction of chronic hyponatremia. Clinical features include quadriplegia, pseudobulbar palsy, and reduced level of consciousness. MRI demonstrates focal demyelination of the pons.

1 2 3 4 5 6 7 8 9 10 11 12 13 14 15 16 17 18 19 20 21 22 23 24 25 26 27 28 29

Decreased plasma osmolality from hyponatremia (common in patients with alcohol abuse) results in water flowing across the osmotic gradient into brain cells; if this happens acutely, life-threatening cerebral edema can occur. However, with slowly developing (chronic) hyponatremia, astrocytes and oligodendrocytes excrete osmotically active organic solutes (eg, glutamate, myoinositol) to cause compensatory intracellular water loss and normalization of brain volume. Therefore, chronic hyponatremia can present with minimal neurologic symptoms.

However, **overly rapid correction of chronic hyponatremia** (eg, bolus of normal saline) reverses the osmotic gradient, drawing water from the cells into the plasma. The astrocytes and oligodendrocytes are unable to rapidly re-accumulate the lost organic solutes, resulting in cell shrinkage, dehydration, and apoptosis. The resultant demyelination preferentially affects the pons, possibly because the cells there are less metabolically active and less able to rapidly regenerate organic solutes.

(Choice A) Vertebrobasilar atheroma formation can result in a pontine stroke with similar symptoms; however, ischemia (not demyelination) is expected on MRI.

(Choice B) Septic emboli (hematogenous spread of bacteria or fungi) are typically associated with endocarditis. Symptomatic brain abscesses can occur (eg, headache, focal neurologic findings), but MRI would demonstrate ring enhancement with vasogenic edema.

(Choice C) The administration of glucose-containing fluids to patients with thiamine deficiency (common in patients with alcohol abuse) can cause Wernicke encephalopathy (ie, ataxia, oculomotor dysfunction, encephalopathy). Korsakoff syndrome (chronic memory impairment) can also occur. Mamillary body atrophy is often visible on MRI.

(Choice E) Paraneoplastic production of anti-neuronal antibodies can be seen in a variety of malignancies (eg, small cell lung cancer, thymoma), but symptoms are often nonfocal (eg, altered mentation, seizures). Demyelination is unexpected.

Educational objective:
Osmotic demyelination syndrome results from overly rapid correction of chronic hyponatremia. Clinical features include quadriplegia, pseudobulbar palsy, and reduced level of consciousness. MRI demonstrates focal demyelination of the pons.

Pathophysiology	Nervous System	Central pontine myelinolysis
Subject	System	Topic

Copyright © UWorld. All rights reserved.

1
2
3
4
5
6
7
8
9
10
11
12
13
14
15
16
17
18
19
20
21
22
23
24
25
26
27
28
29

A 64-year-old man comes to the emergency department due to painless loss of vision in the right eye. The patient's symptoms started suddenly several hours ago and have persisted. He has had no trauma or any similar episode in the past. He has a history of coronary artery disease, atrial fibrillation, and type 2 diabetes mellitus. Blood pressure is 144/86 mm Hg and pulse is 92/min. Cardiovascular examination reveals irregularly irregular rhythm with no murmurs, no peripheral edema, and slightly diminished pedal pulses in both feet symmetrically. Visual acuity in the right eye is hand motion only and normal in the left eye. Funduscopic examination of the right eye is shown in the image below.

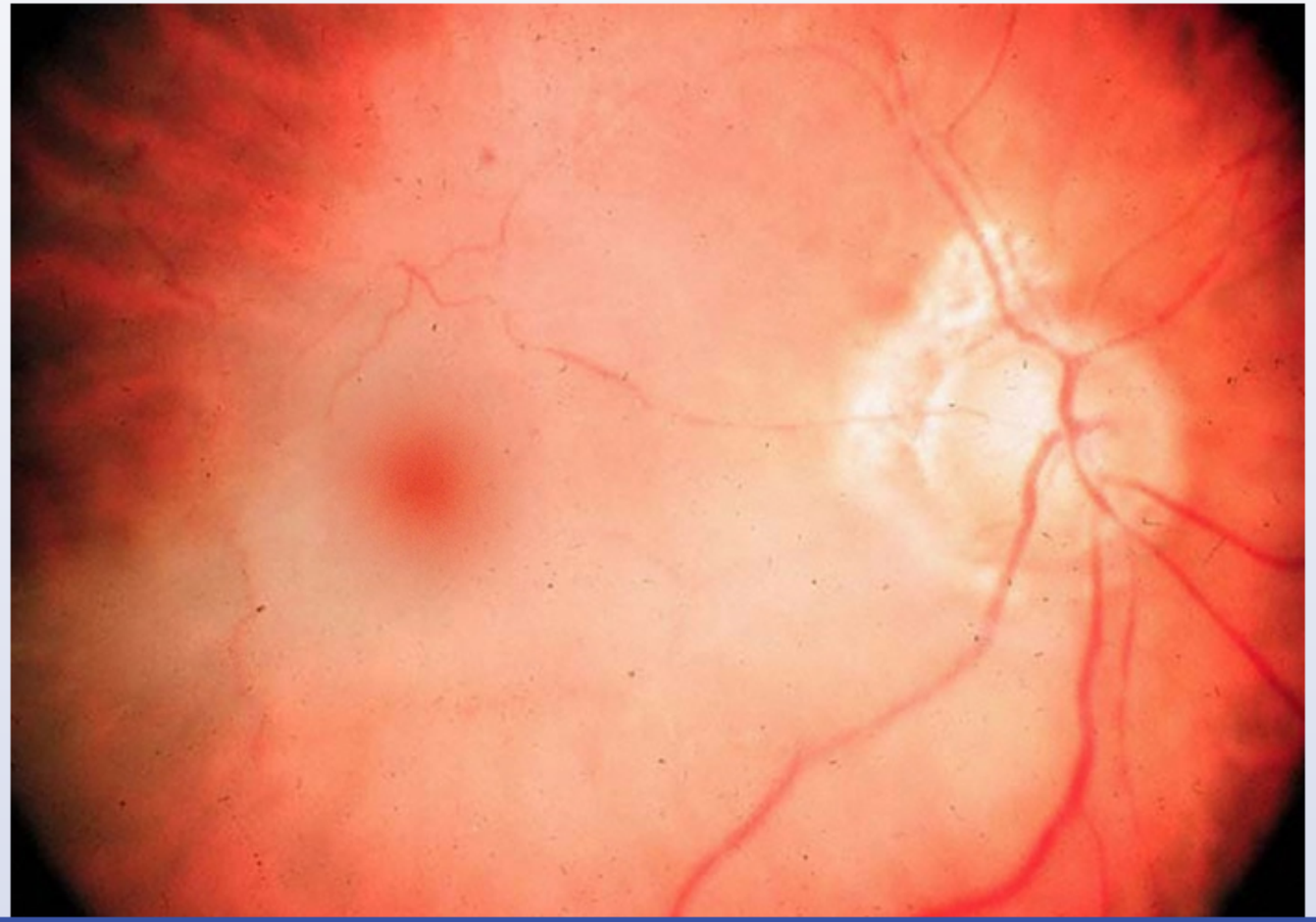

1
2
3
4
5
6
7
8
9
10
11
12
13
14
15
16
17
18
19
20
21
22
23
24
25
26
27
28
29

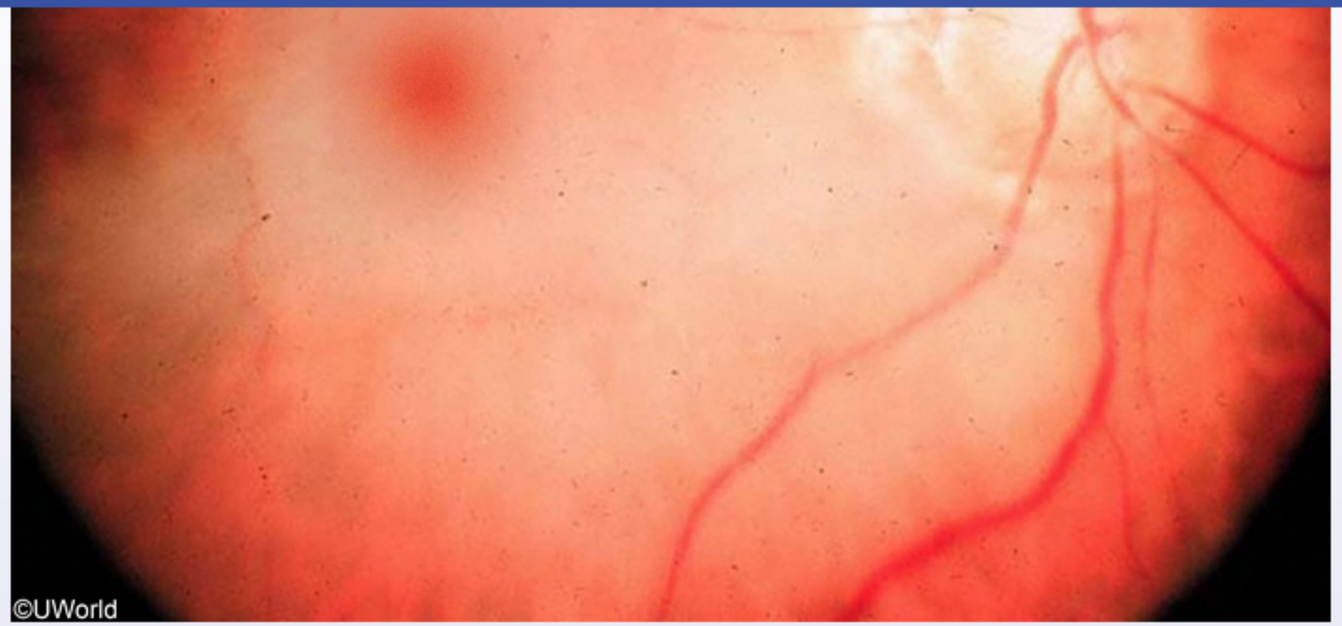

Which of the following is the most likely cause of this patient's loss of vision?

- A. Amaurosis fugax
- B. Diabetic retinopathy
- C. Pituitary adenoma
- D. Retinal artery occlusion
- E. Temporal lobe stroke

Submit

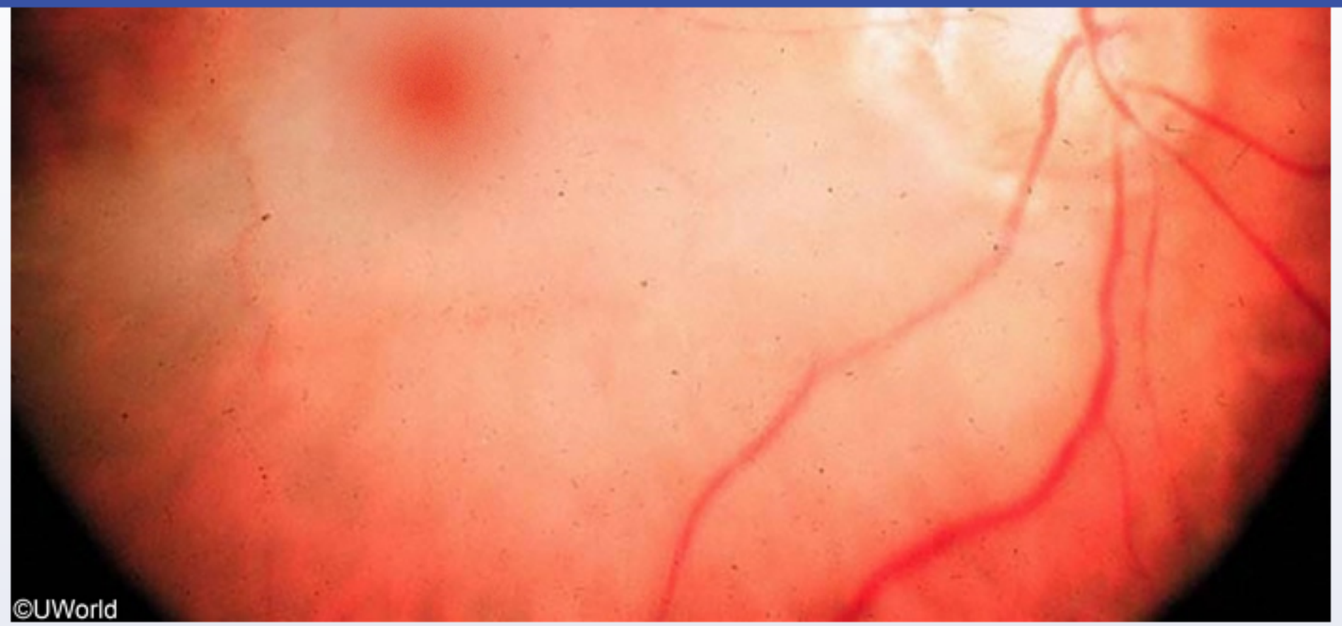

Which of the following is the most likely cause of this patient's loss of vision?

- A. Amaurosis fugax (7%)
- B. Diabetic retinopathy (14%)
- C. Pituitary adenoma (0%)
- ✓ D. Retinal artery occlusion (76%)
- E. Temporal lobe stroke (1%)

Omitted
Correct answer

76%
Answered correctly

09 secs
Time Spent

01/22/2020
Last Updated

1
2
3
4
5
6
7
8
9
10
11
12
13
14
15
16
17
18
19
20
21
22
23
24
25
26
27
28
29

Central retinal artery occlusion

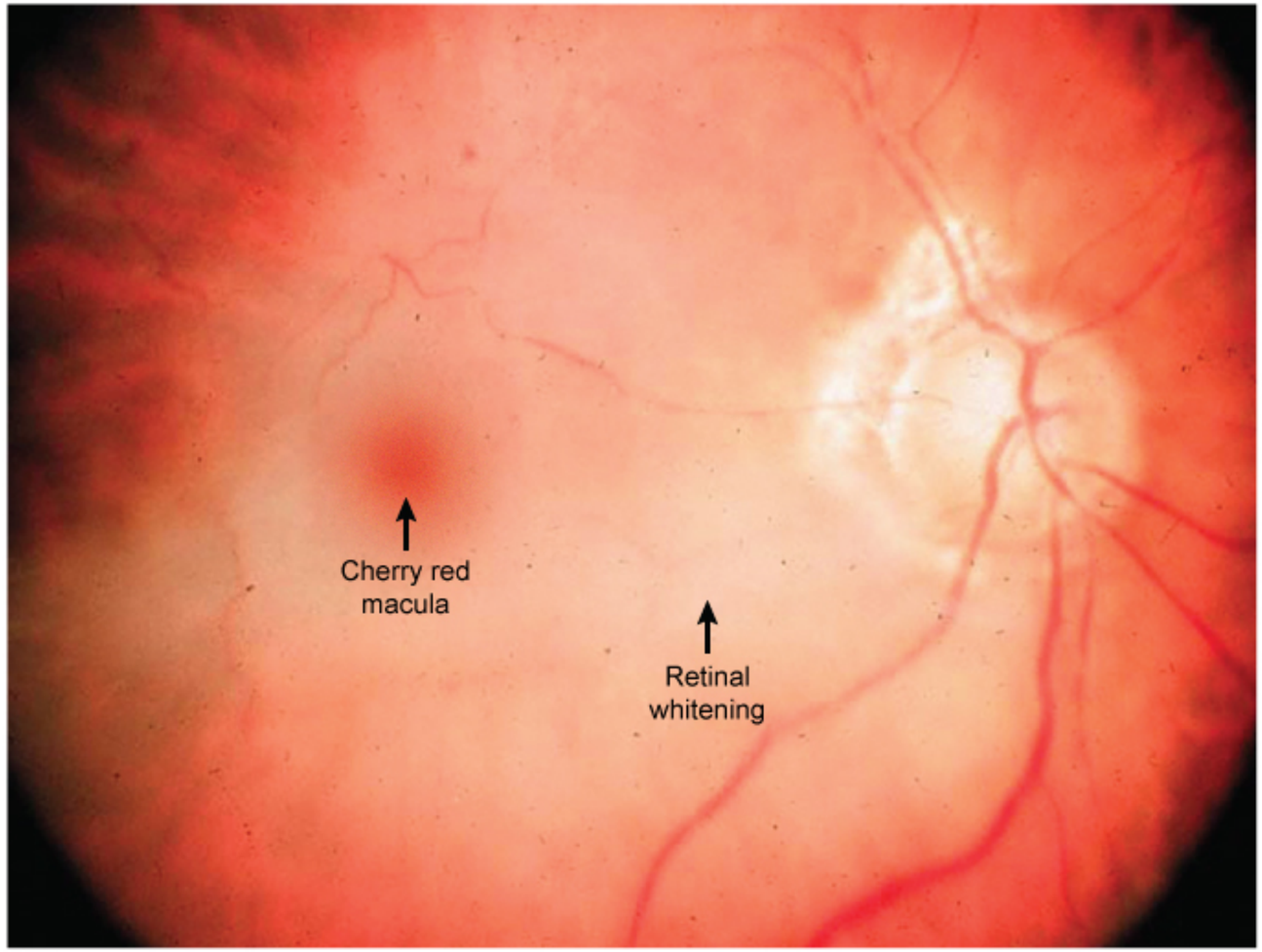

©UWorld

Acute and painless monocular vision loss is characteristic of **central retinal artery occlusion** (CRAO). The vision loss includes the entire visual

©UWorld

Acute and painless monocular vision loss is characteristic of **central retinal artery occlusion** (CRAO). The vision loss includes the entire visual field and is often permanent. Funduscopic findings include a pale retina (due to ischemia and edema) and a **cherry-red macula** (the fovea and foveola are thin and have a separate blood supply from the choroid artery; the red choroid is easily visible underneath).

The central retinal artery is a branch of the ophthalmic artery, which arises from the internal carotid artery. **Athero- and thromboembolism** are the most common causes of CRAO. Predisposing conditions include atrial fibrillation and carotid artery stenosis. CRAO may also be caused by vasculitic diseases (eg, giant cell arteritis).

(Choice A) Amaurosis fugax is a painless, transient, monocular vision loss caused by a small embolus to the ophthalmic artery. It usually does not last more than a few seconds.

(Choice B) Diabetic retinopathy manifests with blurry vision, black spots, floaters, and decreased peripheral vision. Acute visual loss may occur in the setting of a complication such as vitreous hemorrhage, but this patient does not have evidence of neovascularization or hemorrhage.

(Choice C) Large pituitary adenomas may compress the central part of the optic chiasm, causing bitemporal hemianopia.

(Choice E) The lower division of the geniculocalcarine tract (Meyer loop), which carries impulses from the lower retina, passes through the temporal lobe. Temporal lobe infarcts involving the Meyer loop cause contralateral upper quadrantanopsia ("pie in the sky" visual defect).

Educational objective:
Central retinal artery occlusion presents with sudden, painless, and permanent monocular blindness. Funduscopic examination reveals a pale retina and a "cherry-red" macula.

References

- A review of central retinal artery occlusion: clinical presentation and management.

Pathophysiology	Ophthalmology	Retinal artery occlusion
Subject	System	Topic

Copyright © UWorld. All rights reserved.

©UWorld

Exhibit Display

Diabetic retinopathy, proliferative (PDR)

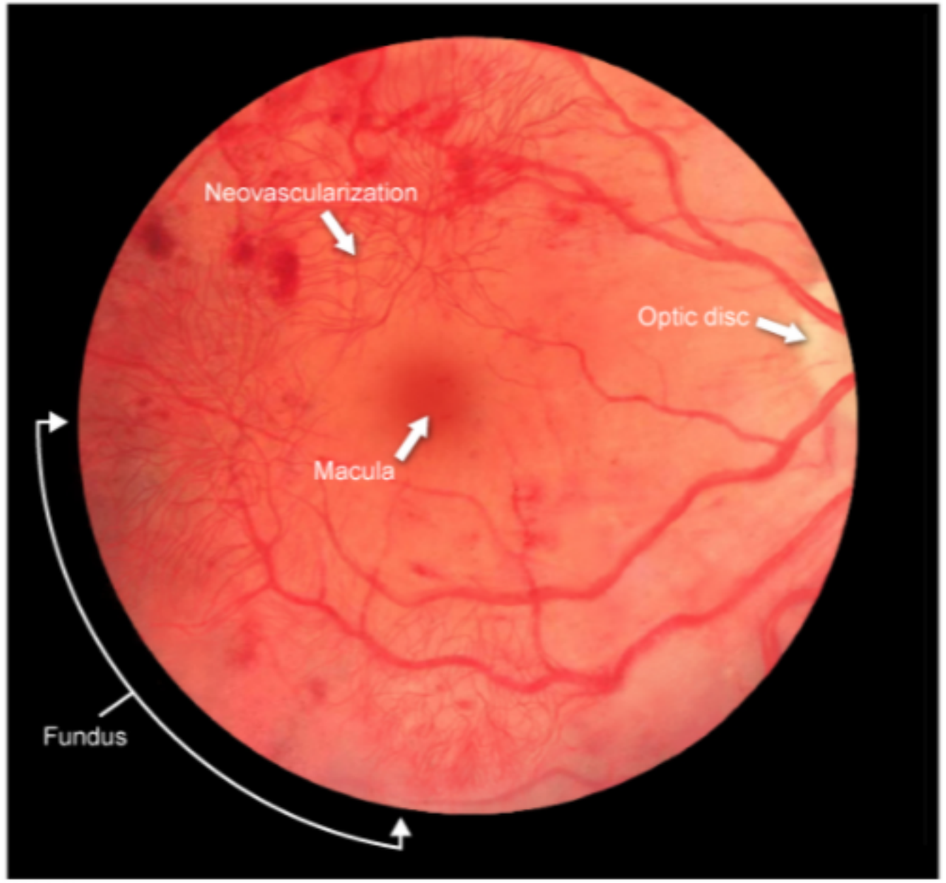

©UWorld

Zoom In | Zoom Out | Reset | Add To New Card | Existing Card